

# Guidelines for the Management of Retinal Vein Occlusion by the European Society of Retina Specialists (EURETINA)

Ursula Schmidt-Erfurth<sup>a</sup> José Garcia-Arumi<sup>b</sup> Bianca S. Gerendas<sup>a</sup>  
Edoardo Midena<sup>c</sup> Sobha Sivaprasad<sup>d</sup> Ramin Tadayoni<sup>e</sup> Sebastian Wolf<sup>f</sup>  
Anat Loewenstein<sup>g</sup>

<sup>a</sup>Department of Ophthalmology, Medical University of Vienna, Vienna, Austria; <sup>b</sup>Hospital Universitari Vall d'Hebron, Barcelona, Spain; <sup>c</sup>Department of Ophthalmology, University of Padua, Padua, Italy; <sup>d</sup>Moorfields Eye Hospital NHS Foundation Trust, London, UK; <sup>e</sup>Department of Ophthalmology, Lariboisière Hospital Paris, Paris, France; <sup>f</sup>Department of Ophthalmology, Inselspital, University of Bern, Bern, Switzerland; <sup>g</sup>Department of Ophthalmology Tel Aviv Medical Center, Sackler Faculty of Medicine, Tel Aviv University, Tel Aviv, Israel

## Keywords

Retinal vein occlusion · Macular edema · Guidelines · Disease management

## Abstract

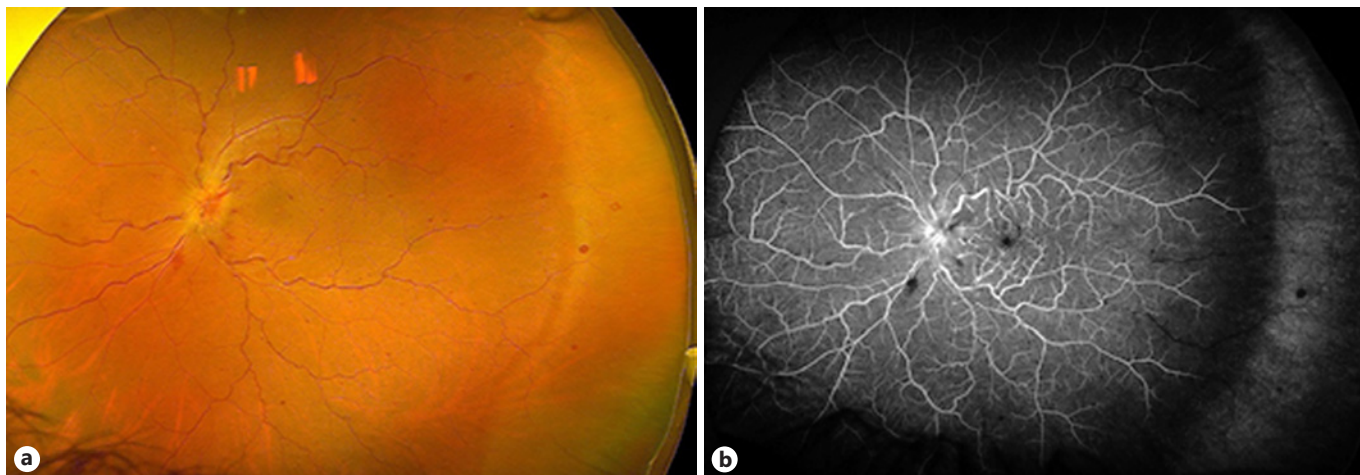
The high prevalence of cardiovascular disease particularly in the elderly population is associated with retinal vascular disease. Retinal vein occlusions represent severe disturbances of the hypoxia-sensitive neurosensory retina. Acute and excessive leakage leads to the diagnostic hallmarks of retinal hemorrhage and edema with substantial retinal thickening. Advanced diagnostic tools such as OCT angiography allow to evaluate retinal ischemia and identify the risk for late complications and will soon reach clinical routine besides fluorescein angiography. Accordingly, the duration of non-perfusion is a crucial prognostic factor requiring timely therapeutic intervention. With immediate inhibition of vascular leakage, anti-VEGF substances excel as treatment of choice. Multiple clinical trials with optimal potential for functional benefit or a lesser regenerative spectrum have evaluated

aflibercept, ranibizumab, and bevacizumab. As retinal vein occlusion is a chronic disease, long-term monitoring should be individualized to combine maintenance with practicability. While steroids may be considered in patients with systemic cardiovascular risk, surgery remains advisable only for very few patients. Destructive laser treatment is an option if reliable monitoring is not feasible. Ophthalmologists are also advised to perform a basic systemic workup to recognize systemic concomitants. The current edition of the EURETINA guidelines highlights the state-of-the-art recommendations based on the literature and expert opinions in retinal vein occlusion.

© 2019 S. Karger AG, Basel

## Introduction

Retinal vein occlusion (RVO) is among the leading causes of visual impairment and is often due to an underlying systemic disease. Advances in imaging and therapeutic possibilities with anti-vascular endothelial growth



**Fig. 1.** Non-ischemic central retinal vein occlusion in a left eye. **a** An ultra-widefield photo exhibits retinal vein dilatation and tortuosity, mainly small or flame-shaped hemorrhages, and optic nerve head edema. **b** An ultra-widefield fluorescein angiogram shows, besides the upper signs on the color fundus image, a late filling of veins but no noteworthy signs of non-perfusion. Images are presented courtesy of Ramin Tadayoni.

factor (VEGF) agents have revolutionized the diagnosis and treatment of this disease. Other therapeutic approaches include use of laser, steroids, and surgery, but for many years anti-VEGF has been accepted as the gold standard. These guidelines give an overview of the different diagnostic and therapeutic strategies available and inform the reader when each should be used.

## Retinal Diagnostics

### Rationale

Different types of RVO share the same characteristic signs on fundus evaluation such as vein dilatation, hemorrhages, edema, and vascular stasis, most commonly in a painless eye presenting with variable degrees of vision alteration.

Diagnosis is then often possible by examining the fundus, conventionally also aided by color fundus photographs or with intravenous fluorescent dye injection (fluorescein angiography, FA). This first section is limited to these clinical features and angiographic manifestations. Optical coherence tomography (OCT) and other tests of interest will be discussed in specific sections later.

### Evidence

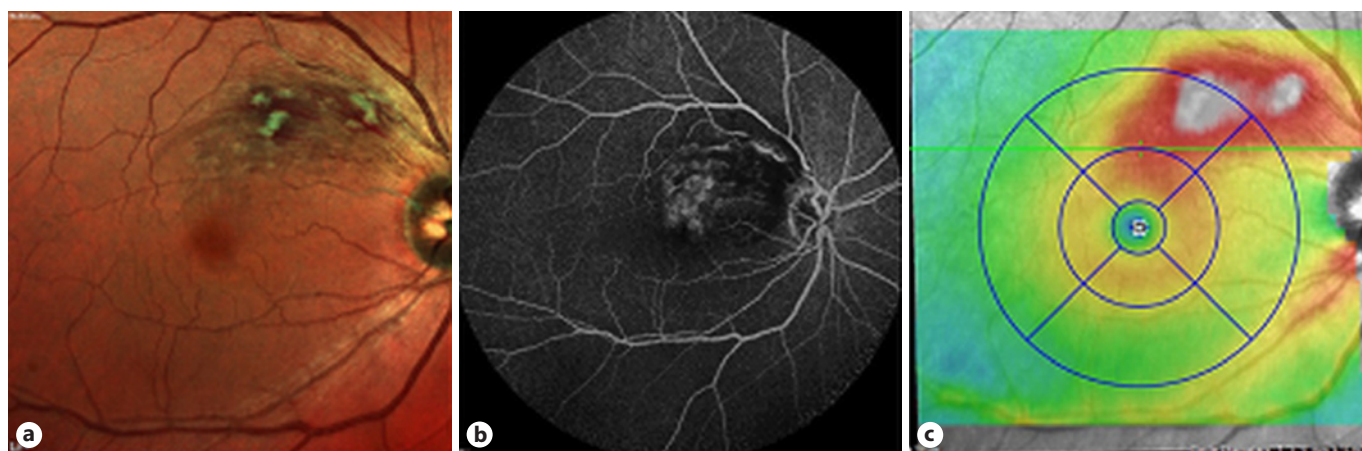
Central vein occlusion (CRVO) is typically associated with loss of vision in one eye in patients older than 40 or, more often, 60 years. Retinal vein dilatation and tor-

tuosity due to an increase in the diameter and length of retinal veins and venules are found on fundus examination and color fundus photographs. Variable degrees of hemorrhages from the optic nerve head to the extreme periphery of the retina are often present. Hemorrhages can appear flame shaped (superficial) or as deep blots (ischemic). Less often the optic nerve head and macular edema can also be present as cotton-wool spots [1] (Fig. 1).

Hemiretinal vein occlusions display similar signs on half of the retina only. They are also called hemispheric vein occlusions if the arteriovenous crossing, that is the site of the occlusion, is visible and are considered a variant of branch retinal vein occlusion (BRVO). When the site is assumed to be behind the lamina cribrosa, it is called hemi-central RVO, and there is no consensus on whether it should be considered part of BRVO or CRVO [2, 3].

Patients with BRVO suffer visual field defects or blurred vision. Signs of vein occlusion are found in the fundus in the area upstream of an arterio-venous crossing considered as the site of the occlusion (Fig. 2). The location and size of the BRVO area differs from a small area upstream of a small venule to the total hemiretina. If macular drainage is not involved and the edema does not reach the macula, visual acuity (VA) can remain normal.

Collateral circulation adjacent to the BRVO area and over the optic nerve head in CRVO and large capillary aneurysms that can cause exudation are signs of a long



**Fig. 2.** Branch retinal vein occlusion in a right eye. **a** A multicolor SLO image of the retina shows retinal vein dilations covered by flame-shaped hemorrhages and cotton-wool spots in a limited area of the posterior pole upstream from the occlusion site of a small retinal vein. **b** A late-phase fluorescein angiogram exhibits leakage in the same area. **c** OCT mapping of retinal thickness confirms the presence of edema in the same area. Images are presented courtesy of Ramin Tadayoni.

duration of the disease. Other rare findings in RVO include a cilioretinal artery occlusion due to the low perfusion pressure in cilioretinal arteries compared with the increased retinal capillary bed pressure [4]. Other cases may, at onset, present as a whitish appearance of the retina around veins considered as severe paracentral acute middle maculopathy (PAMM) (see Features in Optical Coherence Tomography and Angiography) [5].

If RVO has been considered as a diagnosis after fundus examination, three questions need to be asked: is another diagnosis possible? Is there any macular edema? What is the extent of the retinal ischemia?

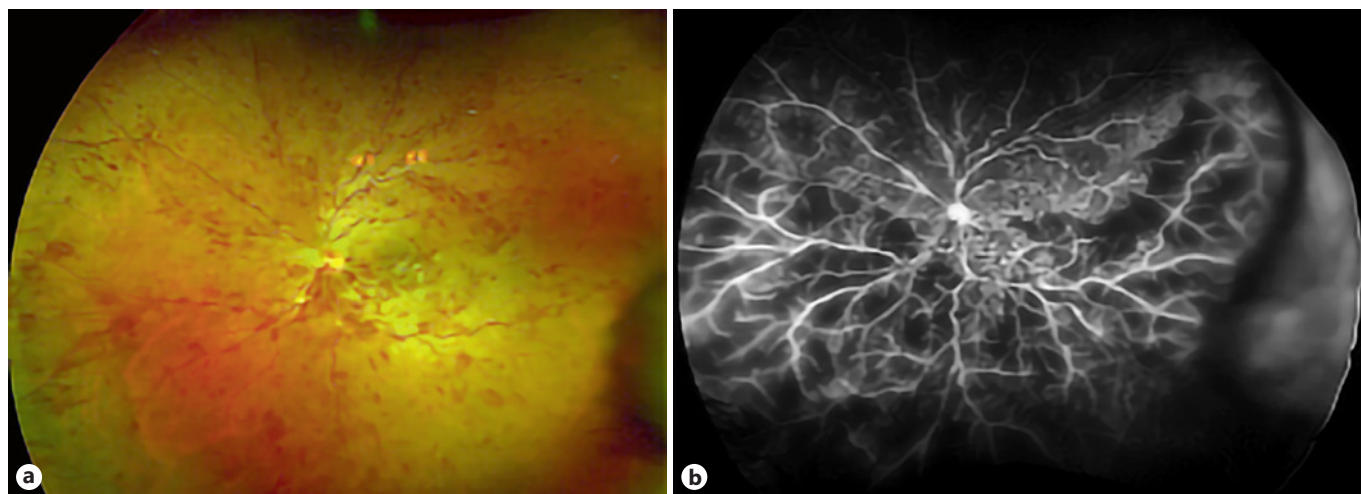
The different diagnoses to consider depend on the clinical presentation of the retina and could be related to any components of the blood circulation: the content of vessels such as blood abnormalities that increase viscosity or alter coagulation, which can lead to retinal hemorrhages (usually in both eyes); upstream arteries such as carotid occlusion, which can also simulate some aspects of vein occlusion; several local vascular diseases such as macular telangiectasias, which can initially be confused with small BRVO (signs are present on both, the superior and inferior temporal side of the fovea, which depends on two different venular branches); or finally a rise in downstream vein pressure such as in a cavernous sinus thrombosis [6–9].

Macular edema can be seen on the fundus as an increase in macular thickness, fluid or exudates in chronic cases and are further described in the next section on fea-

tures in OCT. FA can show vascular leakage in the early or mid-phase and filling of cystic spaces in the late phase. However, today OCT is the best way to diagnose and evaluate macular edema due to RVO.

RVO can lead to an impairment of blood circulation and retinal ischemia. Severe ischemia of the macula alters vision, and extensive peripheral ischemia can lead to retinal and iris neovascularization. When one of these complications is present, the ischemic status of the RVO is clear. Usually in these cases, all signs of RVO are more prominent and can also include cotton-wool spots. Diagnosis of iris neovascularization can be made by clinical examination of the iris and the angle before dilatation as well as by iris FA. If neovascularization obstructs the angle, it can be occluded and increase intraocular pressure (IOP) causing a neovascular glaucoma. Retinal neovascularization can be found on the optic nerve head or on the retinal surface during fundus examination but is more easily visible on FA as abnormal vessels as the site of intense leakage. Neovascularization is associated with a large area of non-perfusion on FA. No consensus exists on the extent or location of macular non-perfusion on FA or OCT angiography that can cause loss of vision. Likewise, no solid consensus exists on the retinal non-perfusion area and risk of neovascularization in BRVO. However, for CRVO the term ischemic CRVO is still commonly used. The SCORE Study Report #11 reports a 36-month incidence of 8.8 and 7.6% of retinal neovascularization in BRVO and CRVO [10].





**Fig. 3.** Ischemic central retinal vein occlusion in a left eye. **a** An ultra-widefield photo exhibits retinal vein dilatation and numerous deep hemorrhages over the entire retina. **b** An ultra-widefield fluorescein angiogram confirms non-perfusion as numerous dark areas are surrounded by a retinal vasculature dead-tree in appearance (no small vessels, only large trunks). Leakage from vessels in these areas also suggests the presence of an extensive area of ischemia. Images are presented courtesy of Ramin Tadayoni.

Ischemic CRVO was defined by the Central Vein Occlusion Study (CVOS) group as the presence of more than 10 disc areas of retinal non-perfusion found on retinal FA with standard 55° technology. The risk of neovascularization in these ischemic CRVO, or “preproliferative” CRVO, cases was judged to be significant as patients developed neovascularization at the rate of almost one in three per year [3, 11]. The diagnosis of ischemic CRVO is then by this definition based on FA. However, at presentation the evaluation of non-perfusion by FA may be challenging, in particular due to the presence of extensive hemorrhages. Consequently, the best way to evaluate the risk of neovascularization at presentation of CRVO remains controversial. Other pointers have been proposed to diagnose such ischemic CRVO including clinical signs such as more prominent indicators of RVO and cotton-wool spots, low VA ( $\leq 0.1$ ) and relative afferent pupillary defect (Fig. 3). Functional tests such as electroretinography, visual field or microperimetry, or composite scores have also been proposed but are less used. In practice, if initially not possible due to extensive hemorrhage, non-perfusion is evaluated once hemorrhages decrease after intravitreal injections [12]. By this time, it can be estimated by the extent of signs on the fundus and VA alteration at first presentation. The iris and retina are then closely monitored until the high risk of neovascularization is ruled out or appropriate treatment for neovascularization has been applied. A non-ischemic CRVO can also convert

to an ischemic CRVO during follow-up in about 25/28.6% of CRVO/BRVO cases [13].

Two new imaging technologies, OCT angiography (see Features in Optical Coherence Tomography and Angiography) and ultra-widefield FA (UWF-FA), have recently shown promise for evaluating non-perfusion. The advantage of the UWF-FA is that it can display a much larger surface of the retina. The CVOS definition of 10-disc areas of retinal non-perfusion cannot be applied to this entire area. The size of the non-perfusion area in the peripheral retina beyond the area reached by 55° FA that is predictive of the risk of developing neovascularization remains unclear. The percentage of non-perfused surface in the retina visible on UWF-FA images has been proposed as a prognosis factor (called “ischemic index”), but larger studies are needed to assess this proposal [14, 15]. Moreover, the extent of image distortion (usually an overestimation of the periphery compared with central areas), depending on the material and software used, also has to be addressed. Indeed, none of the definitions of the ischemic index consider the location of the non-perfusion areas.

### Recommendation

Whenever an RVO is suspected, a full ophthalmologic examination in particular including a VA measurement, an iris examination to rule out neovascularization, and a fundus examination should be undertaken. Taking the

medical history and the examinations into account, the various possible diagnoses should be considered and the presence of macular edema as well as the extent of the retinal ischemia evaluated. For this last evaluation, establishing the relation between the extent of change in VA and non-perfusion on FA can be helpful. If hemorrhage precludes reliable evaluation of retinal perfusion on FA, this examination can be done after a few injections (if required) as they often clean the fundus significantly. Monitoring of signs of ischemia and neovascularization should continue during follow-up at least by monitoring VA, the iris, and the fundus.

## Features in Optical Coherence Tomography and Angiography

### Rationale

OCT is the most commonly used imaging modality in RVO. The fast-emerging new technologies, mainly swept-source OCT technology, are especially useful as they allow microstructural and near histologic imaging. Densely spaced volume scans create high-resolution images, where many different features can be distinguished. In addition, the introduction of OCT angiography allows even more detailed analysis in a non-invasive way. In RVO, the identified features look very much like those of chronic diseases such as diabetic macular edema (DME), but with the acute onset of CRVO and BRVO there may be other features or the same features can be interpreted differently.

Central retinal thickness (CRT), defined as the mean thickness of the retina between its inner and outer boarders on all a-scans taken in the central 1-mm area, is the most used OCT feature. CRT has been the major endpoint in most randomized clinical trials: its increase correlates with functional loss, whereas its decrease correlates with functional gain [16, 17]. CRT measurements are used to evaluate disease activity and progression as well as the treatment response in each individual patient and can be imaged with any OCT device. Evaluation of high-resolution images reveals features on a more detailed level. Among others, intraretinal fluid (IRF)/cystoid fluid (usually used for the same entity: any IRF of which most is organized as cystoid spaces), subretinal fluid (SRF), hyperreflective foci (HRF), or different retinal layers and their thickening, thinning, or disruption, especially in the photoreceptor layers, can be distinguished. Evaluation of OCT angiography mainly allows interpretation of the retinal vessel density in the different retinal

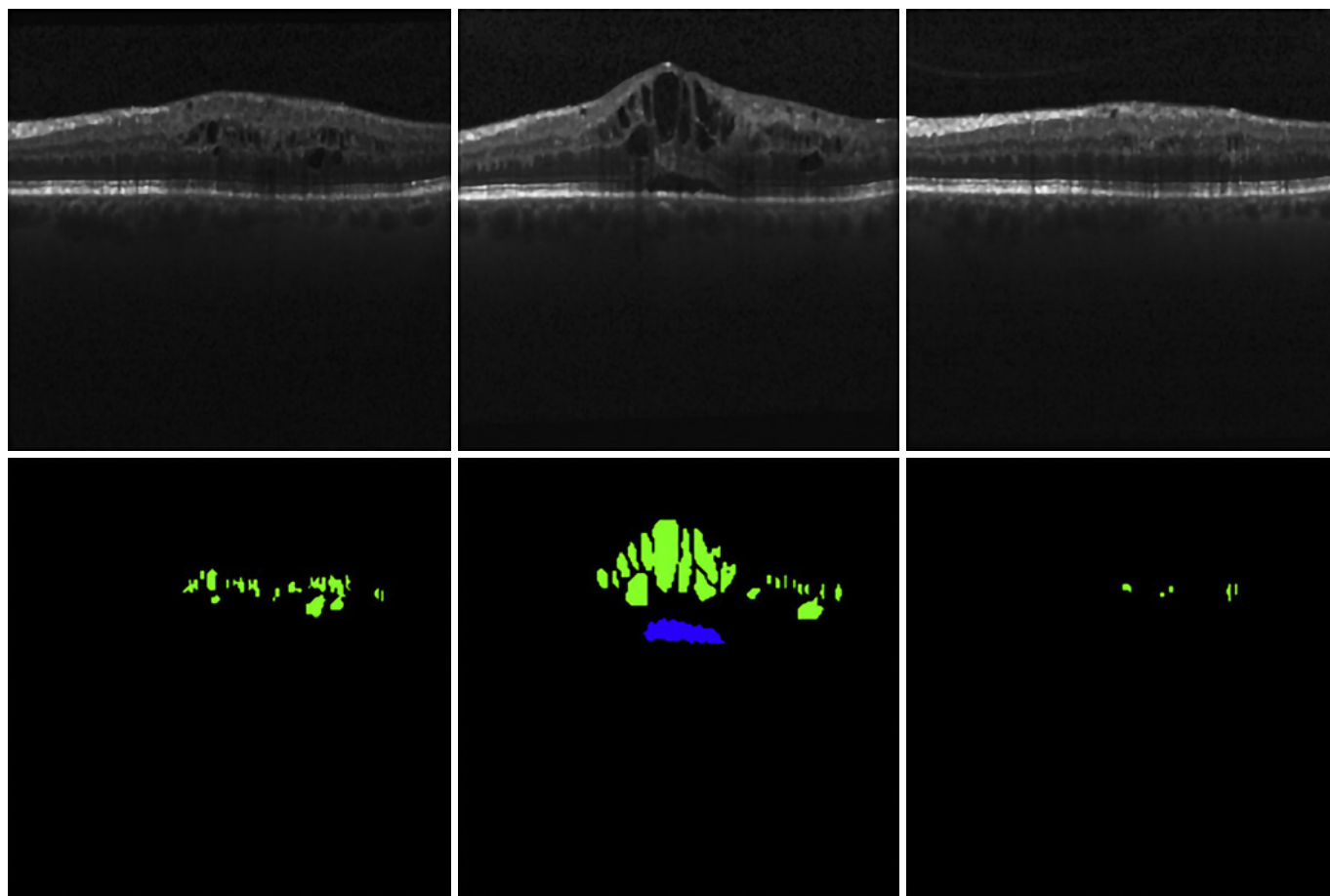
plexus or measuring the size of the foveal avascular zone. It can also visualize collaterals of the regular retinal microvasculature and be used to evaluate the extent of ischemic areas.

### Evidence

As with other retinal diseases, OCT can be used for diagnosis, staging, observation, and the individual treatment response of macular edema in RVO. Many publications have shown the different morphologic features and their correlation to function and most of them can be only imaged with OCT. SRF (the non-reflective space between the neurosensory retina and the retinal pigment epithelium) and IRF (the minimally reflective round or oval spaces within the neurosensory retina) are signs for acute macular edema (Fig. 4). Disorganization of the inner retinal layers (DRIL), integrity changes in the inner and outer photoreceptor segment line, and the external limiting membrane show damage to the retinal structure that may lead to irreversible cell loss and associated functional loss. HRF as well as vitreomacular abnormalities (e.g., traction, epiretinal membrane) can be imaged in different disease states of RVO. Signs of ischemia in RVO have been reported as a prominent middle limiting membrane (p-MLM) and PAMM.

Most randomized clinical trials have used CRT as the primary endpoint. CRT has always been the primary morphologic endpoint, starting with the BRAVO (Branch Retinal Vein Occlusion) and CRUISE (Central Retinal Vein Occlusion) trials, where CRT measured on time-domain OCT was used, but it was also used in trials such as CRYSTAL (Ranibizumab Intravitreal Injections in Patients with Visual Impairment due to Macular Edema Secondary to Central Retinal Vein Occlusion) or BRIGHTER (Efficacy and Safety of Ranibizumab with or without Laser in Comparison to Laser in Branch Retinal Vein Occlusion), where spectral-domain OCT was the modality of choice [16, 17]. However, there are many publications showing that there is an individualized need for decisions based on morphology in RVO [18, 19].

The CRYSTAL and BRIGHTER studies have been analyzed in detail for morphology-based research. These were two 24-month, phase IIIb, open-label, multicenter studies with 812 patients in total that assessed the efficacy and safety of an individualized dosing regimen of 0.5 mg ranibizumab driven by VA stabilization criteria in CRVO and BRVO (see also Anti-VEGF Agents) [16, 17]. One main factor predicting functional outcomes in macular edema due to RVO is the response to treatment in a spatiotemporal morphologic analysis. By analyzing data



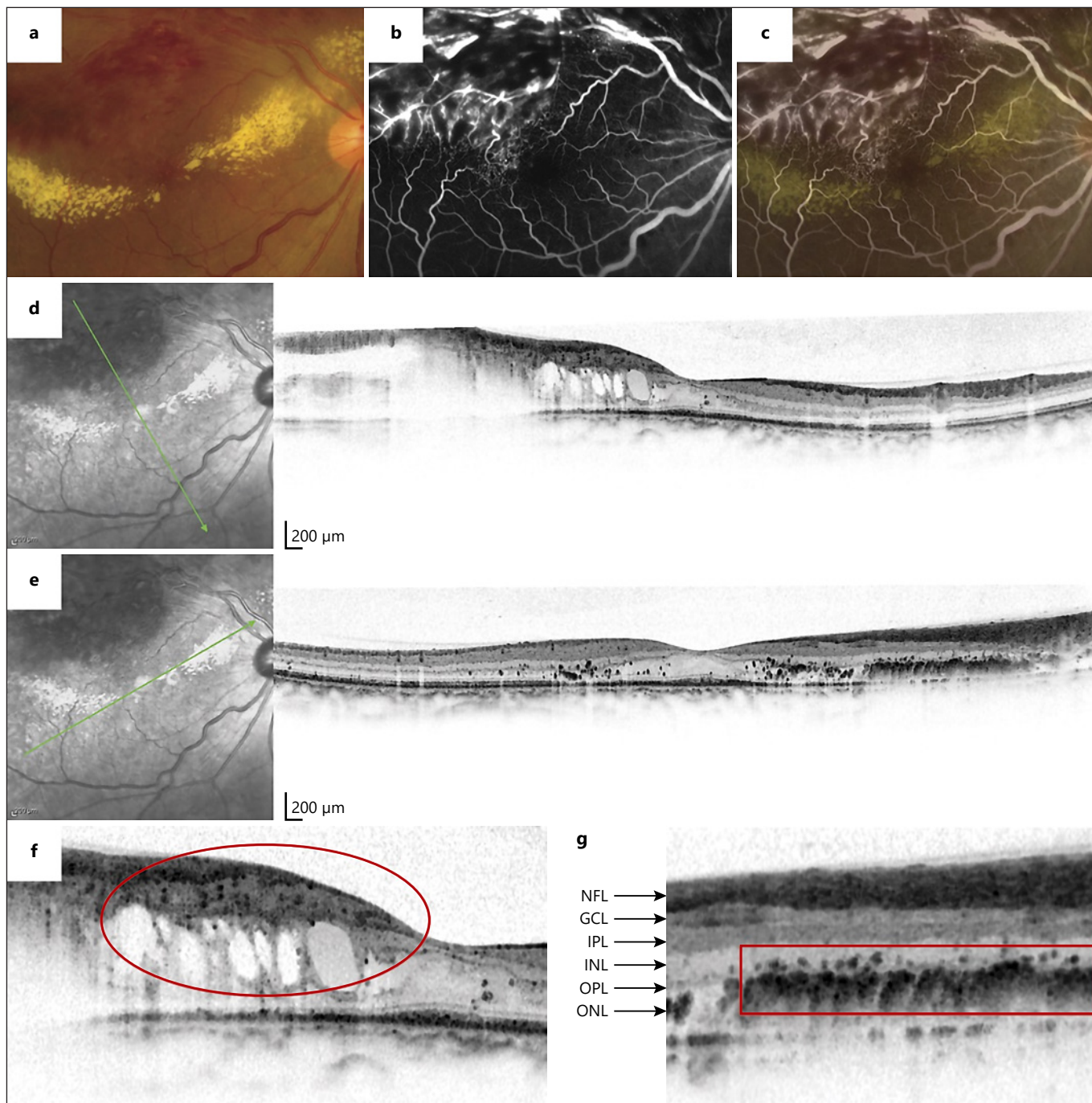
**Fig. 4.** Subretinal fluid (SRF) non-reflective space between the neurosensory retina and the retinal pigment epithelium (blue) and intraretinal fluid (IRF) minimally reflective round or oval spaces within the neurosensory retina (green) are signs for acute macular edema. Automatic segmentation of IRF and SRF with deep learning is possible in RVO. Adapted with permission from Schlegl et al. [158].

from the three initial injections, it is possible to predict if edema will recur within the study period [20]. Using fluid for the prediction of outcomes in addition to clinical and VA data increased the prediction accuracy. Nevertheless, VA at baseline had the largest impact on VA outcomes after the study interval [21]. An analysis of the impact of the vitreomacular interface status in patients from these trials showed larger best-corrected visual acuity (BCVA) gains in eyes with than without vitreomacular adhesion (BRVO:  $15 \pm 12$  vs.  $11 \pm 11$  letters,  $p = 0.02$ ; CRVO:  $18 \pm 14$  vs.  $9 \pm 13$  letters,  $p < 0.01$ ) despite those with vitreomacular adhesion receiving a similar number of retreatments [22]. Another subanalysis of these studies could show that neuroretinal atrophy (predominantly retinal thinning in the inner plexiform to outer nuclear retinal layer compartment in focal macular areas) can fol-

low ranibizumab therapy in RVO but is not associated with poorer VA outcomes [23]. The fact that CRYSTAL resulted in a statistically significant BCVA gain in a broad population of patients, including those with macular ischemia at baseline, supports the notion that focal ischemia or atrophy may not be associated with worse VA outcomes in RVO [16].

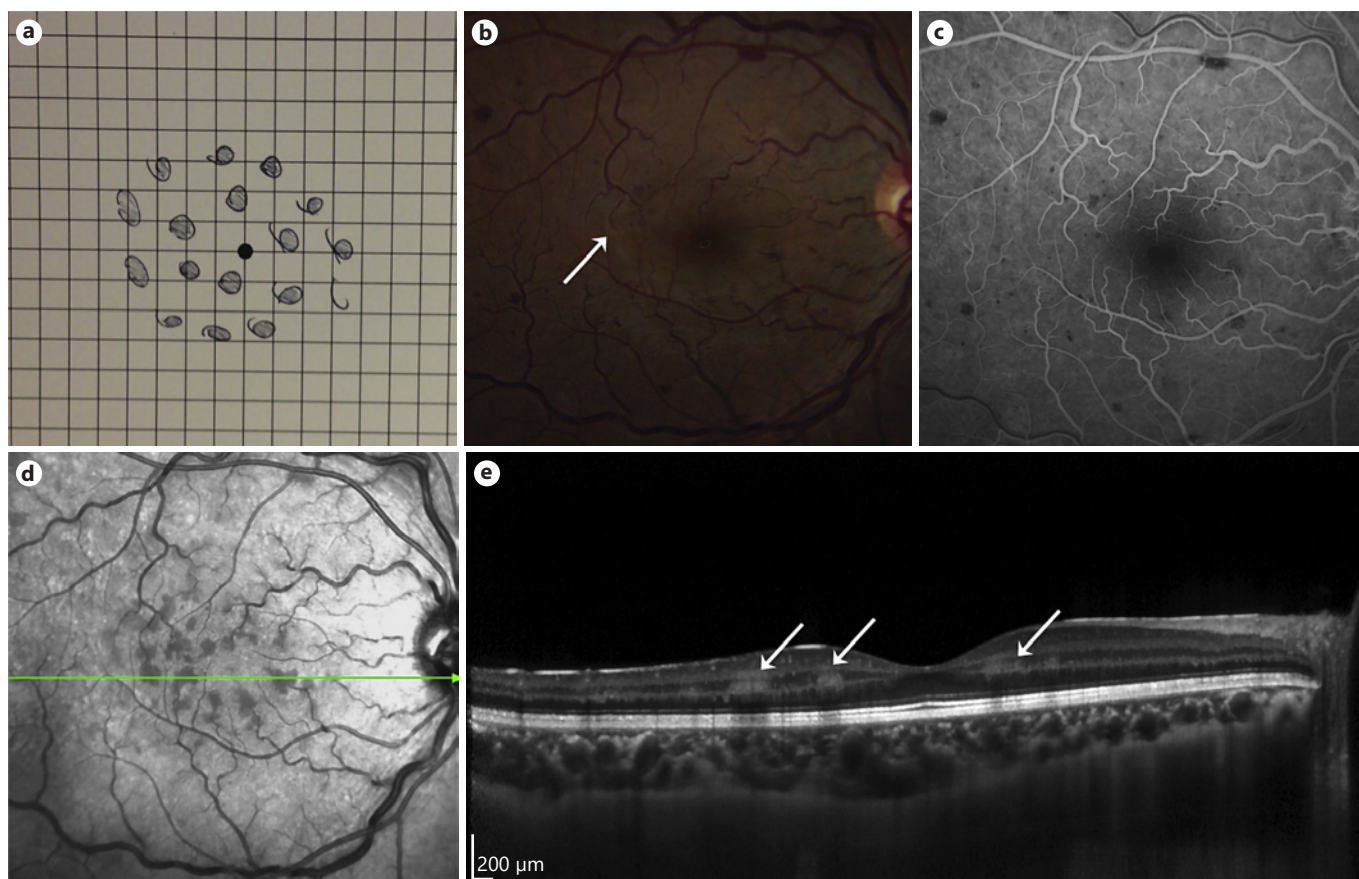
Some studies with few patients have investigated the importance of other morphologic features. A study of 39 patients with BRVO (combined with patients with DME) has shown that HRF are associated with poorer visual outcomes and a reduction of HRF can be achieved with anti-VEGF or steroid treatment [24]. The same study also showed that the number of HRF is higher in patients with more thickening of the retina. Furthermore, the more HRF were present, the more likely pho-





**Fig. 5.** Color fundus photograph (a), early-phase (b) and late-phase (c) FAs, and superimposed images of branch retinal vein occlusion 3 years after symptom onset (d). A Spectralis OCT image corresponds to the green arrow in the infrared image (e), and its magnified image shows fine hyperreflective foci in the occluded

area (g) and confluent hyperreflective foci in the inner and outer sides of the outer plexiform layer (f). NFL, retinal nerve fiber layer; GCL, ganglion cell layer; IPL, inner plexiform layer; INL, inner nuclear layer; OPL, outer plexiform layer; ONL, outer nuclear layer. Adapted with permission from Ogino et al. [27].



**Fig. 6.** A patient with paracentral acute middle maculopathy. **a** A 37-year-old woman receiving therapy for active pulmonary tuberculosis presented with acute vision loss in the right eye and noted that pieces of central vision were missing, as illustrated by Amsler grid testing. **b** Visual acuity was 20/25 at presentation, and retinal examination of the right eye was consistent with acute central retinal vein occlusion and perivenular retinal whitening in the temporal macula (solid arrow). **c** Fluorescein angiography was unre-

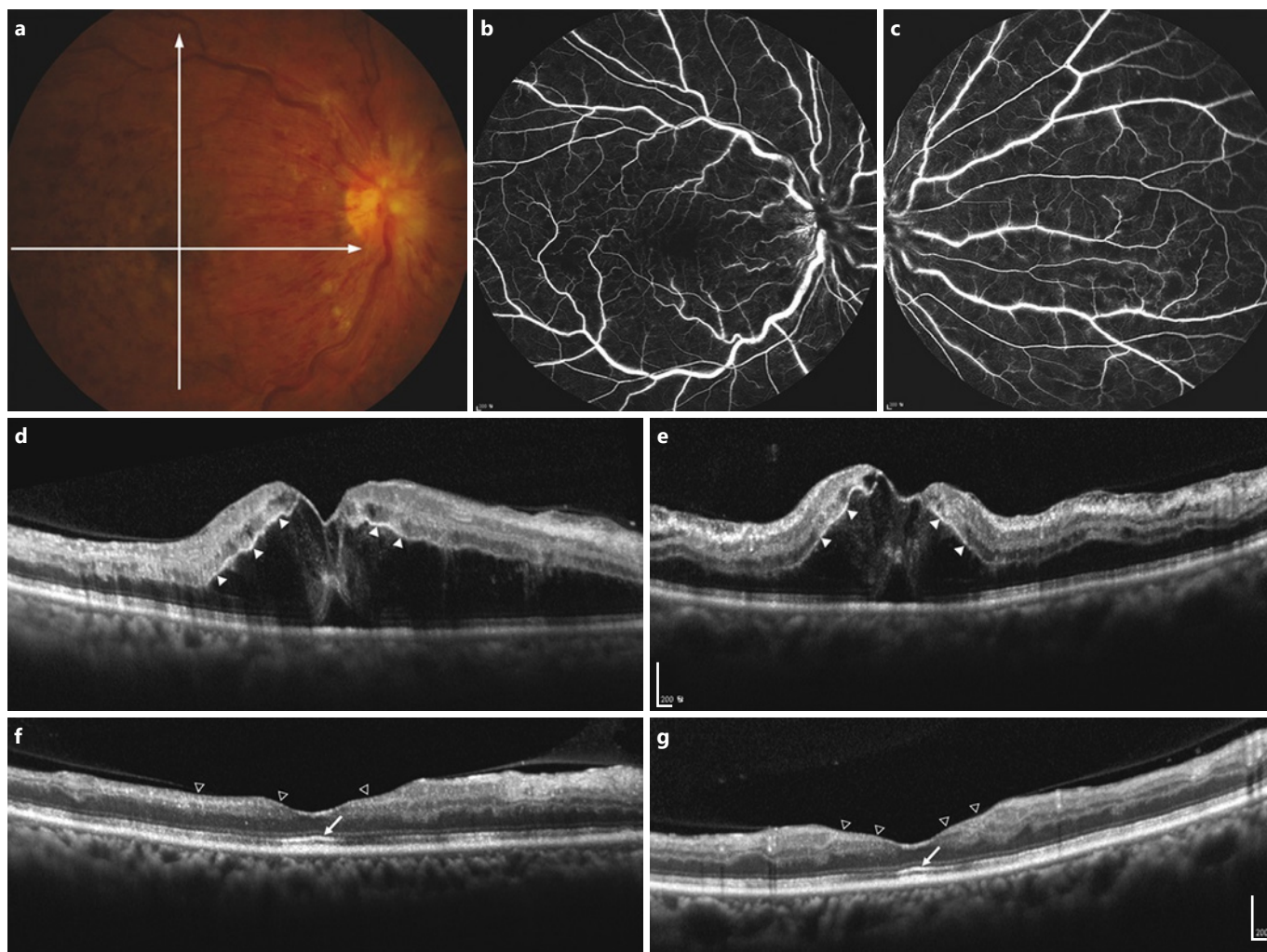
markable. **d** Near-infrared reflectance imaging demonstrated multifocal dark gray lesions at the terminal tips of the venous branches corresponding to the retinal whitening observed clinically. **e** Spectral-domain optical coherence tomography revealed multiple hyper-reflective plaque-like lesions involving the inner nuclear layer (solid arrows) consistent with paracentral acute middle maculopathy. Adapted with permission from Rahimy et al. [29].

toreceptor layer (inner and outer photoreceptor segment line and the external limiting membrane) disruption occurred, which most probably accounted for the worse VA outcomes in these patients [24]. Two other studies of 50 and 97 patients, respectively, with BRVO and CRVO specify this finding even more, as they analyzed the position of HRF with regard to their depth location. In both studies, the HRF in the outer retinal layers were the best prognostic factor for therapy outcome of anti-VEGF treatment when the photoreceptor disruption status was analyzed and correlated with VA [25, 26]. The accumulation of HRF looks different from that in DME. In DME, HRF usually accumulate around fluid departments, whereas in RVO most HRF accumulate

around the outer plexiform layer regardless of the fluid around them [27] (Fig. 5).

Another study of 136 eyes with macular edema due to RVO analyzed the impact of DRIL and DRIL over time on VA [28]. The researchers concluded that greater DRIL extent at baseline correlates with worse baseline VA (point estimate, 0.04; 95% confidence interval [CI], 0.01–0.07 per 100  $\mu\text{m}$ ,  $p = 0.003$ ). The change in the DRIL extent following the first three monthly anti-VEGF injections identified eyes with a high likelihood of subsequent VA improvement or decline. Therefore, the extent of DRIL before and after treatment represents an additional OCT variable that may serve as a biomarker for patients with macular edema due to RVO [28].





**Fig. 7.** Acute ischemic retinopathy of CRVO followed by late-phase inner retinal atrophy. A 55-year-old female patient without any previously known medical or ophthalmologic history complained of sudden visual loss (best-corrected visual acuity of 20/400) lasting 4 days before presentation. **a** On fundus examination, tortuous dilated retinal veins with multiple retinal hemorrhages and cotton-wool spots were observed and diagnosed as CRVO. There was a delayed arteriovenous transit time in fluorescence angiography. However, areas with capillary non-perfusion were mixed with perfused areas at the macula (**b**) and peripheral retina (**c**) making it difficult to measure the size of the non-perfused area. **d, e** OCT shows a prominent line of hyperreflectivity

near the synaptic portion of outer plexiform layer (marked with white triangles), the prominent middle limiting membrane. During follow-up, she had three intravitreal anti-VEGF injections for resolution of the macular edema. **f, g** After 4 months, the macular edema was completely resolved, but atrophic areas of the inner retina remained (marked with vacant triangles) and visual acuity remained unimproved (20/400); note that the integrity of the outer nuclear layer and the photoreceptor layer, which are supplied by the choroidal circulation, remained well preserved at the final visit (marked with white arrows). Adapted with permission from Ko et al. [30].

PAMM and p-MLM signs have been described to predict the development of ischemic areas in eyes with RVO. One study analyzed OCT images of 484 patients for “hyper-reflective spectral-domain OCT lesions involving the middle layers of the retina at the level of the inner nuclear layer” (Fig. 6) and concluded that these may develop in response to ischemia of the intermediate and deep capil-

lary plexuses. Importantly, PAMM was associated with focal VA loss [29]. Another study analyzed the p-MLM sign in RVO as “a hyperreflective line located in the inner part of the outer plexiform layer” (Fig. 7) as an indicator of acute ischemic retinal damage in 50 patients with CRVO and found patients with p-MLM had a statistically significant worse VA outcome [30].

Many studies focus on the correlation between morphologic features and VA, and underline their importance as potential biomarkers. Most of these studies look at a single or few imaging biomarkers at a time. The Vienna group has subanalyzed all the morphologic features in one patient cohort (CRYSTAL and BRIGHTER subset with Spectralis OCT of 682 patients) to identify which imaging biomarker is best for assessing the structure-function correlation. The only predictive features from 15 potential morphologic biomarkers were CRT, SRF, HRF and IRF. However CRT itself was the most predictive one, closely linked to the existence of IRF. Individual morphologic changes in RVO such as an acute onset of disease have little impact on baseline VA. Photoreceptor alterations in particular do not seem to play such a significant role as they do in other (chronic) diseases, for example DME and neovascular age-related macular degeneration (AMD) [Michl et al., unpubl. data].

In RVO, OCT angiography generally shows reduced retinal vessel density in all plexuses in the affected eye compared to the unaffected fellow eye of the same patient. In comparison to FA, OCT angiography can detect the extent of ischemic RVO in most cases, but it misses some [31]. A few studies have described the association of a smaller mean perfusion area or the often present foveal avascular zone enlargement on OCT angiography with worse VA outcomes after anti-VEGF therapy or a higher mean number of edema recurrences [31–38]. It is also possible to visualize abnormal retinal vessels which may be intraretinal and therefore not very well visible for the clinician [39].

### Recommendation

OCT is a useful modality to diagnose macular edema due to RVO. Unlike in other retinal diseases, the magnitude of the impact of individual morphologic changes on VA remains unclear. Nevertheless, there are features that seem to play an important role. HRF in the outer plexiform layer have an especially negative impact on VA prognosis. Additionally, CRT is a robust variable because RVO is an acute-onset disease and may not show as many long-term changes as chronic retinal diseases. The photoreceptor status has no direct influence on VA at the time of the acute onset of the disease but plays an important role in VA prognosis after therapy. OCT angiography is a good addition to monitor the retinal microvasculature over time. It is recommended to use it in addition to regular OCT imaging when available. At baseline, the patient should be imaged with OCT angiography in addition to FA.

The exact impact of each feature in OCT and OCT angiography is still to be determined in large randomized clinical trials; therefore, the recommendation is to monitor disease activity with OCT at regular intervals and re-treat based on VA (as the strongest predictor for later VA) and CRT. These recommendations are based on evidence levels I and II.

## Therapeutic Strategies

### Laser Therapy

#### Rationale

Laser photocoagulation is the standard of care for the treatment of neovascular complications associated with RVO [11, 40]. The mechanism of panretinal laser photocoagulation (PRP) has been attributed to the destruction of ischemic retina, leading to an improved blood supply to the remaining retina and decrease in VEGF production [41]. Prior to the introduction of anti-VEGF therapy, focal laser photocoagulation was used in macular edema secondary to BRVO [42].

#### Evidence

For patients with CRVO, the CVOS provided evidence for indication, treatment, and follow-up for PRP [11, 40]. Prophylactic PRP did not prevent the development of iris or angle neovascularization in eyes with extensive capillary non-perfusion (10 or more disc areas). Therefore, PRP was recommended only after iris neovascularization was visible, requiring a weekly or biweekly follow-up of patients with extensive capillary non-perfusion. Where close follow-up is not possible, prophylactic PRP should be considered as early PRP (within 90 days of onset of the CRVO) can prevent iris neovascularization in ischemic CRVO [43].

Argon laser is usually used for PRP, with laser spots applied outside the vascular arcade extending anterior as far as possible. In general, 1,500–2,500 spots with a diameter of 500 µm are applied. Peripheral transscleral cryocoagulation may be considered for eyes with hazy media where laser photocoagulation is not possible. Laser spots should only be applied in the affected retinal areas of patients with BRVO [44].

The Branch Vein Occlusion Study (BVOS) provided evidence that focal laser photocoagulation statistically improves VA in patients with macular edema secondary to BRVO [42]. Until the introduction of anti-VEGF therapy, this treatment was the standard of care for macular edema secondary to BRVO [45–49]. Di-

rect comparison between anti-VEGF intravitreal therapy and focal laser photocoagulation showed that the outcome after anti-VEGF therapy was statistically significantly better than after focal laser photocoagulation. About twice as many patients had a three-line improvement after anti-VEGF therapy than after focal laser photocoagulation [48, 49]. For more details on the comparative studies, please refer to the section on anti-VEGF agents.

### Recommendation

PRP is the standard of care for the treatment of neovascular complications associated with RVO. These include retinal and disc neovascularization secondary to BRVO or CRVO as well as iris neovascularization [11, 40]. Laser treatment can be withheld in patients with extensive retinal ischemia who require close follow-up until neovascularization is detected. Otherwise, prophylactic laser photocoagulation should be considered [43]. Laser treatment for macular edema secondary to BRVO has been shown to be effective for visual improvement [42] but in view of the availability of anti-VEGF therapy, focal laser photocoagulation should be considered only as a second-line treatment [45–47].

### Anti-VEGF Agents

#### Rationale

The rationale for anti-VEGF therapy of macular edema following RVO is based on the observation that intraretinal VEGF mRNA transcription and intraocular VEGF levels were increased in patients with RVO compared with a control group [50–54]. VEGF increases vessel permeability by increasing the phosphorylation of tight junction proteins and is thus an important mediator of the blood-retinal barrier breakdown leading to vascular leakage and macular edema [53]. Therefore, therapy that inhibits VEGF is an effective therapeutic modality targeting the underlying pathogenesis of macular edema in RVO [47, 52]. Consequently, anti-VEGF intravitreal therapy has become the standard of care for treating this disease. Currently, two anti-VEGF agents have been approved by the European Medicines Agency (EMA) and the US Food and Drug Administration (FDA) for the treatment of macular edema due to RVO: ranibizumab (Lucentis; Genentech Inc., South San Francisco, CA, USA) and aflibercept (Eylea®; Regeneron Pharmaceuticals Inc., Tarrytown, NY, USA, and Bayer HealthCare Pharmaceuticals, Berlin, Germany). Bevacizumab (Avastin; Genentech, South San Francisco, CA, USA/Roche, Basel, Switzerland) is additionally used for this indication on an off-label basis [47, 55].

### Ranibizumab

#### Rationale

Ranibizumab is a humanized, recombinant, affinity-matured VEGF monoclonal antibody fragment, designed for intraocular use that binds to and neutralizes all isoforms of VEGF-A and their biologically active degradation products [47, 51, 52]. Today, it has an established role in the treatment of AMD and DME [47, 51]. Several studies have reported the efficacy and safety of ranibizumab in the treatment of macular edema secondary to RVO, and long-term data recently became available allowing the evaluation of continued therapeutic effects [56, 57].

#### Evidence

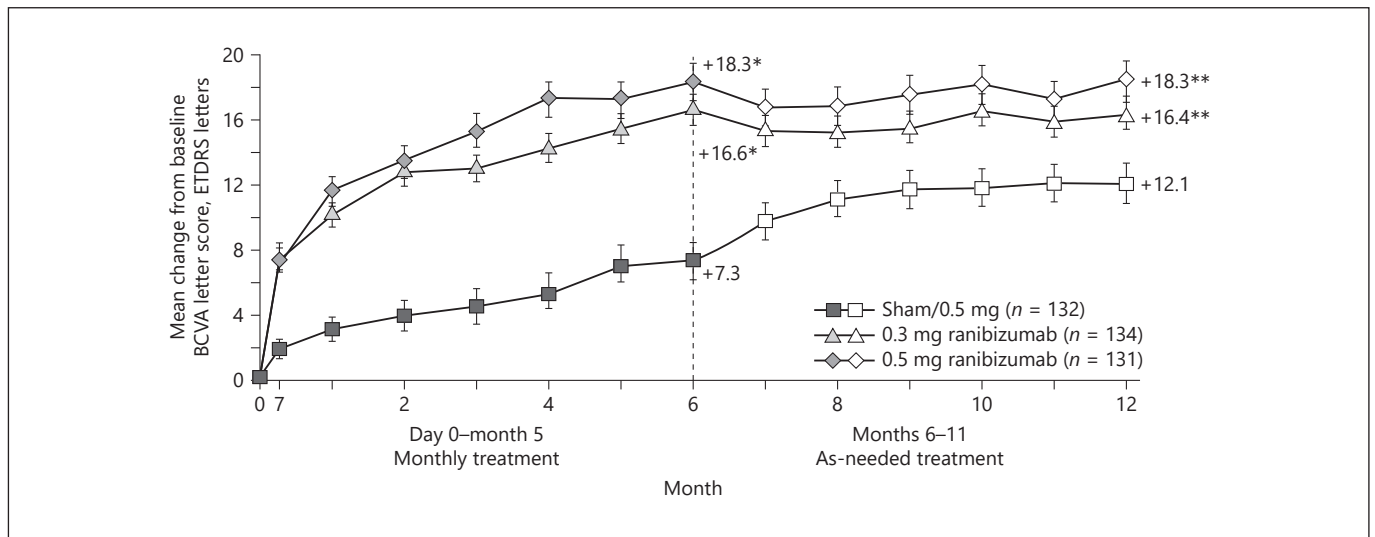
Ranibizumab versus Sham and Ranibizumab versus Grid-Laser

The BRAVO and the CRUISE trials, two phase III, multicenter, randomized studies, were the first to provide evidence of the efficacy of monthly intravitreal injections of ranibizumab in patients with macular edema following BRVO and CRVO diagnosed within 12 months before enrollment [47, 51]. After 6 months in the BRAVO trial, patients with BRVO treated with 0.3 or 0.5 mg intravitreal ranibizumab had a significantly superior functional outcome compared with patients treated with sham injections. Mean BCVA changes from baseline were +16.6 and +18.3 letters for the 0.3 and 0.5 mg ranibizumab arm, respectively, versus +7.3 letters for the sham arm; a 15-letter BCVA gain from baseline in 55.2 and 61.1% of the 0.3 and 0.5 mg ranibizumab arm, respectively, versus 28.8% for the sham arm ( $p < 0.0001$  for each ranibizumab group vs. sham, for both analyses) [47] (Fig. 8).

Similar results were reported for patients with CRVO in the CRUISE trial. The mean BCVA changes from baseline were +12.7 and +14.9 letters for the 0.3 and 0.5 mg ranibizumab arm versus +0.8 letters in the sham group; a 15-letter BCVA gain from baseline in 46.2 and 47.7% of the 0.3 and 0.5 mg ranibizumab arm, respectively, versus 16.9% in the sham group ( $p < 0.0001$  for each ranibizumab group vs. sham, for both analyses) [51] (Fig. 9).

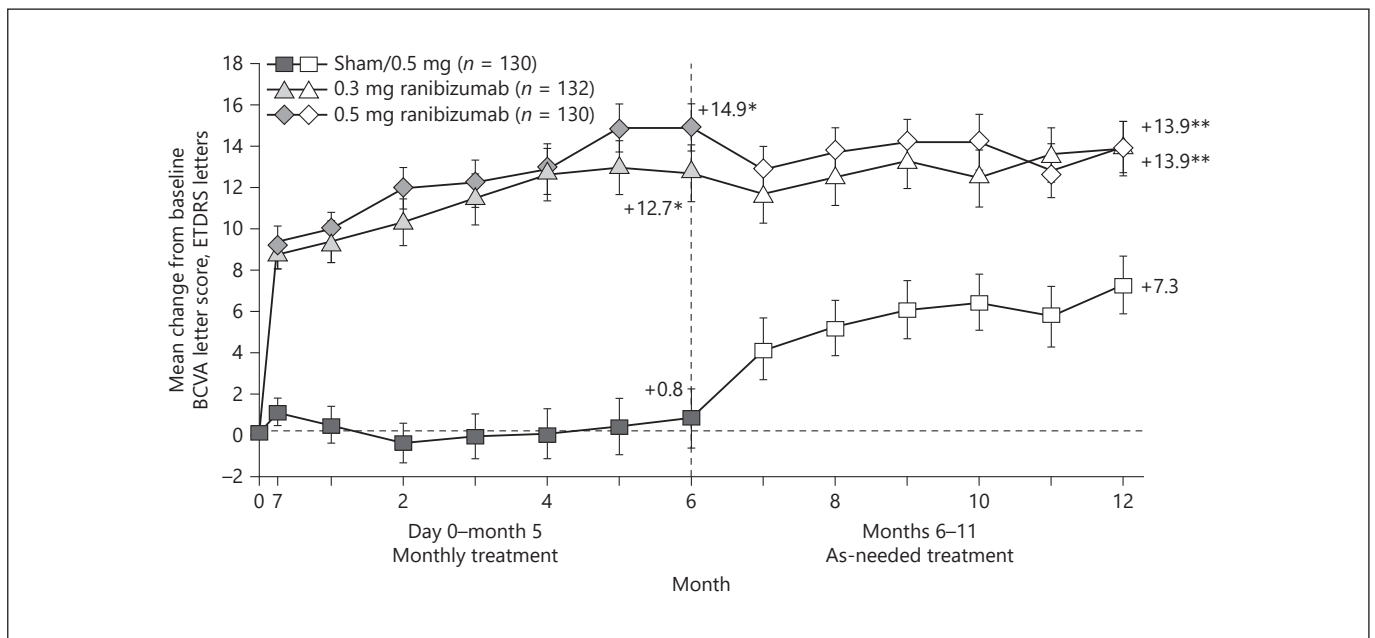
BCVA improvement was rapid and dramatic in both ranibizumab groups, with patients gaining an average 7.5 (BRVO) and 9 (CRVO) letters 7 days after the first injection. The mean BCVA improvement was greater in all treatment groups of both studies for patients affected by BRVO <3 months before study screening compared with those diagnosed  $\geq 3$  months before screening. The mean change in BCVA at month 6 was greater for patients with worse BCVA and CRT >450  $\mu\text{m}$  at baseline [47, 51].





**Fig. 8.** The BRAVO Study. Mean change from study eye baseline best-corrected visual acuity (BCVA) letter score over time to month 12. \*  $p < 0.0001$  vs. sham, \*\*  $p < 0.01$  vs. sham/0.5 mg. Earliest statistically significant group difference was at day 7. The last observation carried forward method was used to impute missing values. Vertical bars are  $\pm 1$  standard error of the mean. On average, visual gains during the treatment period were maintained in

the ranibizumab treatment groups during the observation period. There was substantial improvement in VA in the sham/0.5 mg group during the observation period; however, the mean change from baseline BCVA score of sham/0.5 mg group remained significantly different from that of the 0.3 and 0.5 mg groups at month 12. ETDRS, Early Treatment Diabetic Retinopathy Study [46].



**Fig. 9.** The CRUISE Study. Mean change from study eye baseline best-corrected visual acuity (BCVA) letter score over time to month 12. \*  $p < 0.0001$  vs. sham, \*\*  $p < 0.001$  vs. sham/0.5 mg. Earliest statistically significant group difference was at day 7. The last observation carried forward method was used to impute missing values. Vertical bars are  $\pm 1$  standard error of the mean. On average, visual gains during the treatment period were maintained in

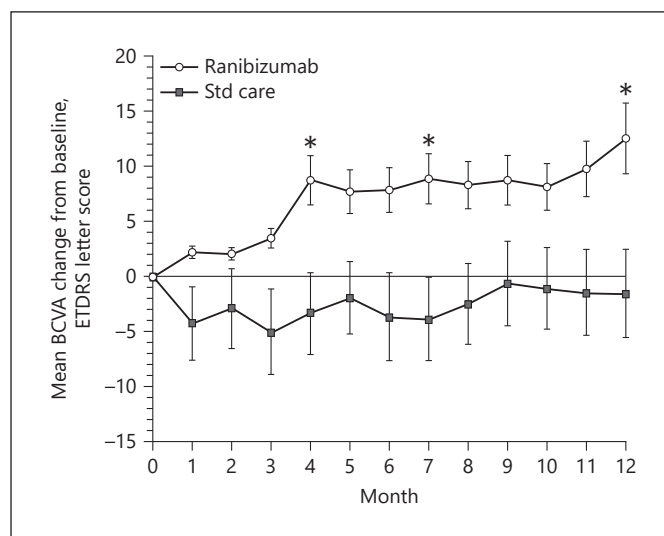
the ranibizumab treatment groups during the observation period. There was substantial improvement in visual acuity in the sham/0.5 mg group during the observation period; however, the mean change from baseline BCVA score of the sham/0.5 mg patients remained significantly different from that of the 0.3 and 0.5 mg groups at month 12. ETDRS, Early Treatment Diabetic Retinopathy Study [58].

Concomitant with the improvement in BCVA, there was a rapid and dramatic reduction in CRT after treatment with ranibizumab (at day 7, CRT mean reduction from baseline was  $>250\ \mu\text{m}$  in both ranibizumab groups compared with no reduction in the sham group) [47, 51].

During a subsequent 6-month observation period, all patients (including the sham group) could receive monthly intravitreal ranibizumab based on prespecified OCT and VA criteria (pro re nata; as needed [PRN]). At month 12, the 0.3 and 0.5 mg treatment groups maintained CRT reduction with ranibizumab PRN (CRT mean reduction  $-313.6\ \mu\text{m}$  and  $-347.4\ \mu\text{m}$  in the BRAVO study, and  $-452.8\ \mu\text{m}$  and  $-462.1\ \mu\text{m}$  in the CRUISE study); the sham group (then mostly having received ranibizumab 0.5 mg for 6 months PRN) also improved in CRT, with a mean reduction from baseline of  $-273.7\ \mu\text{m}$  in the BRAVO (still significantly lower than in ranibizumab groups,  $p < 0.05$ ) and  $-427.2\ \mu\text{m}$  in the CRUISE at month 12 (not significantly lower than ranibizumab groups,  $p > 0.40$ ) [46, 58]. During this observation period, the mean number of ranibizumab injections (PRN) was 2.8 and 3.8 in the 0.3 mg, 2.7 and 3.3 in the 0.5 mg, and 3.6 and 3.7 in the sham group of the BRAVO and CRUISE studies, respectively.

Most patients who did not receive any injection showed worsening of BCVA from month 6 to 7, whereas most of those who received an injection showed improvement in BCVA [46, 58] (Fig. 8, 9). However, at month 12, both ranibizumab groups (0.3 and 0.5 mg) maintained BCVA improvements ( $+16.4$  and  $+18.3$  letters from baseline in BRVO patients and  $+13.9$  letters for both groups in patients with CRVO). The sham group improved ( $+12.1$  and  $+7.3$  letters from baseline in BRAVO and CRUISE, respectively), still statistically significantly less than the ranibizumab groups [46, 58]. (Fig. 8, 9). At month 12, the percentage of patients who obtained a Snellen equivalent  $\geq 20/40$  (generally considered an excellent outcome) was 43.2 and 43.1% in the 0.3 and 0.5 mg groups and 34.6% in the sham group in BRAVO and 67.9, 66.4, and 56.8% in CRUISE [46, 47, 51, 58].

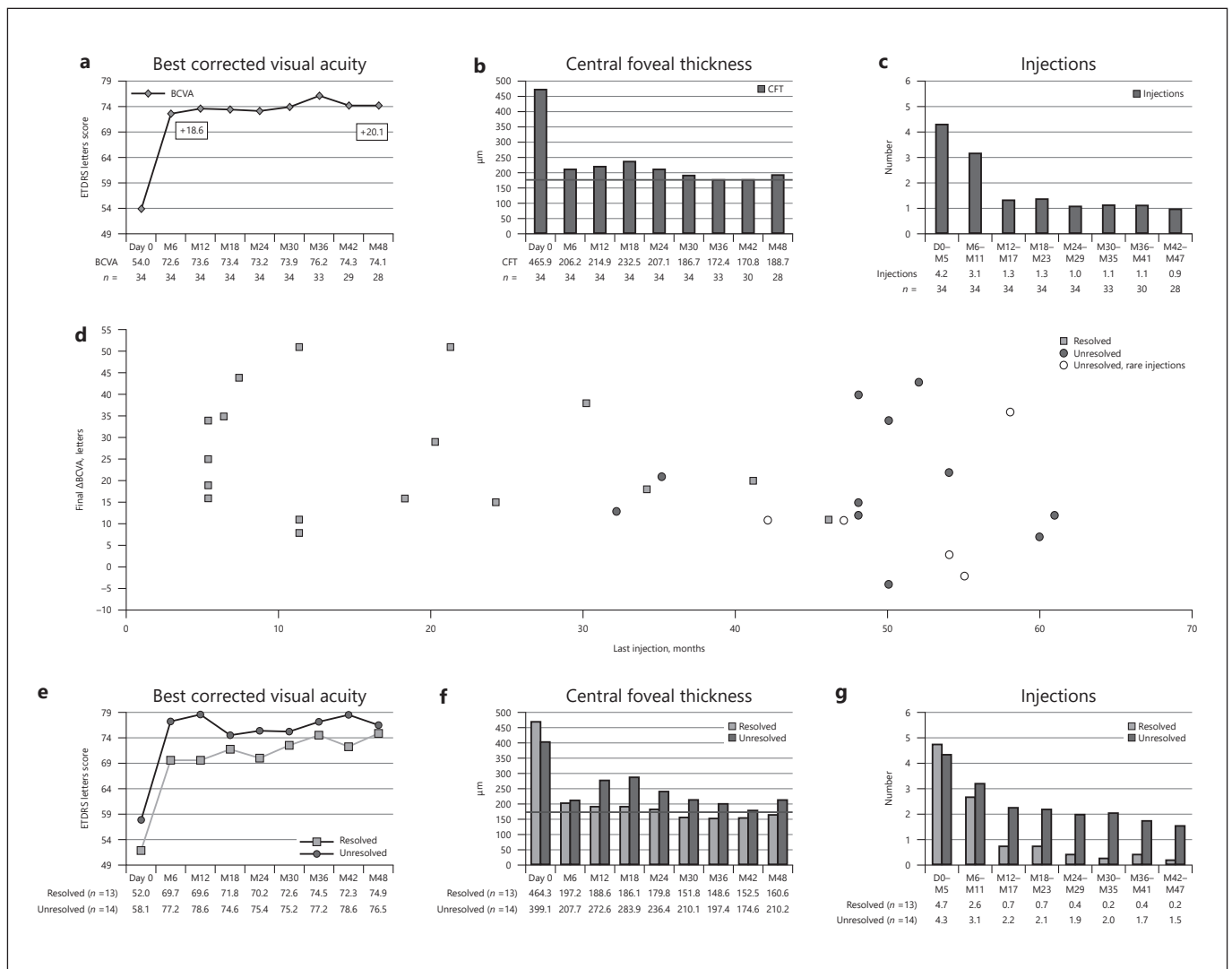
Based on these results, ranibizumab was approved by the FDA and the EMA for this indication in 2010 and 2011 [46]. However, these trials did not compare the effectiveness of intravitreal ranibizumab against grid laser photocoagulation, which was the current standard of care at that time and was used in these trials only as rescue treatment for all patients. A later study demonstrated the greater efficacy of intravitreal 0.5 mg ranibizumab compared with conventional macular grid laser in patients with perfused macular edema following BRVO with a vi-



**Fig. 10.** Graph of mean change from baseline best-corrected visual acuity (BCVA) letter score in the study eye over time to month 12 in patients receiving intravitreal ranibizumab vs. standard grid laser for macular edema following branch retinal vein occlusion. Each plot represents the mean gain or loss in BCVA letter score compared to baseline at that particular time point in the study eye of patients receiving intravitreal ranibizumab (represented by round plots) vs. patients receiving standard grid laser (represented by square plots). Higher BCVA letter scores were obtained in patients receiving intravitreal ranibizumab compared to patients receiving grid laser at all time points. The difference in BCVA letter score between the 2 groups was statistically significant at months 4, 7, and 12 (indicated by \*  $p < 0.05$ ). The last observation carried forward was used to input missing data. Vertical error bars denote standard error of the mean. ETDRS, Early Treatment Diabetic Retinopathy Study. From Tan et al. [45].

sion loss duration between 6 weeks and 9 months prior to the baseline visit. The study was a multicenter, masked, randomized, placebo-controlled study, registered at the Australian New Zealand Clinical Trials Registry [45]. It differed from BRAVO as after 6 months of monthly injections both groups could receive monthly intravitreal 0.5 mg ranibizumab or sham injections based on prespecified OCT and VA PRN criteria [42, 45].

At month 12, the 0.5 mg ranibizumab group was statistically significantly superior to the laser group in functional outcome (mean BCVA change from baseline  $+12.5$  and  $-1.6$  letters for the ranibizumab and sham groups). A 15-letter BCVA gain from baseline was achieved in 53 and 19% of the ranibizumab and sham groups, respectively [45] (Fig. 10). BCVA improvement was already seen in the ranibizumab group at month 1, while in the laser group the maximum BCVA decrease was seen at



**Fig. 11.** The RETAIN Study. Graphs showing that patients with branch retinal vein occlusion treated with ranibizumab have an excellent long-term outcome. **a** Mean best-corrected visual acuity (BCVA) in Early Treatment Diabetic Retinopathy Study (ETDRS) letter score is plotted at 6-month intervals from first entry into the Ranibizumab for the Treatment of Macular Edema following Branch Retinal Vein Occlusion: Evaluation of Efficacy and Safety (BRAVO) study. **b** Mean CFT (center point thickness by Stratus optical coherence tomography [Carl Zeiss Meditec Inc., Dublin, CA, USA]) is plotted at 6-month intervals from first entry into BRAVO. Dark gray line represents a value of 172  $\mu$ m, the mean CFT reported in normal patients. **c** Mean number of injections per 6-month interval from first entry into BRAVO. **d** Final change in

BCVA ( $\Delta$ BCVA) plotted against the time after BRAVO baseline when the last injection of ranibizumab was given for resolved patients (no edema for at least 6 months after last injection of ranibizumab; gray squares), unresolved patients (black circles), and unresolved patients who required rare injections (white circles). **e** Mean BCVA plotted at 6-month intervals for resolved patients (no edema for at least 6 months after last injection of ranibizumab; gray squares) vs. unresolved patients (black circles). **f** Mean CFT plotted at 6-month intervals for resolved (gray) vs. unresolved (black) patients. Dark gray line represents a value of 172  $\mu$ m, the mean CFT reported in normal patients. **g** Mean number of injections per 6-month interval for resolved (gray) vs. unresolved (black) patients [56].

month 3. The percentage of patients who obtained a Snellen equivalent  $\geq 20/40$  at month 12 was 60.0 and 28.6% in the ranibizumab and laser groups, respectively [45]. At weeks 13 and 25, 6.7 and 8.3% of patients receiving rani-

bizumab required rescue laser compared with 68.4 and 50% of patients receiving sham, respectively ( $p = 0.0004$  and 0.039). In the PRN period, the frequency of injections every 8–12 weeks was in accordance with that reported in



the BRAVO study, although the retreatment regimens used differed slightly [45–47]. After a 1-year study period, combining laser with ranibizumab did not seem to provide any advantage compared with ranibizumab monotherapy in terms of improving BCVA and treatment exposure in patients with BRVO [45].

#### Long-Term Follow-Up

After completion of the BRAVO and CRUISE trials, patients were offered enrollment in an open-label, multicenter extension study to evaluate the safety and tolerability of ranibizumab (HORIZON Study) and were seen at least every 3 months and treated with 0.5 mg ranibizumab on VA and OCT criteria in a PRN regimen. After 1 year, all three original treatment groups in CRUISE showed a statistically significant reduction in the mean change in BCVA letter score from baseline, whereas there was no significant difference from baseline in the BRAVO groups [57].

The RETAIN Study (extended follow-up of patients with macular edema due to branch retinal vein occlusion or central retinal vein occlusion previously treated with intravitreal ranibizumab) was a following open-label, single-arm, multicenter extension trial that included patients who completed the BRAVO or CRUISE trials and had subsequent follow-up in HORIZON [56]. At their final visit, the mean BCVA change in patients with BRVO was +20.1 letters from the BRAVO baseline with a 15-letter BCVA gain in 61.8%; in patients with CRVO, it was +14.0 letters with a 15-letter BCVA gain in 53.1% (not statistically different from the improvement at the end of the BRAVO and the CRUISE studies for the same cohorts of patients) (Fig. 11, 12). The percentage of patients who obtained a Snellen equivalent  $\geq 20/40$  was 79.4% for patients with BRVO and 43.8% for those with CRVO. The mean number of ranibizumab injections per year was 2.6 and 4.5 in year 2, 2.1 and 3.6 in year 3, and 2.0 and 3.3 in year 4 for patients with BRVO and CRVO, respectively [47, 51, 56] (Fig. 11, 12).

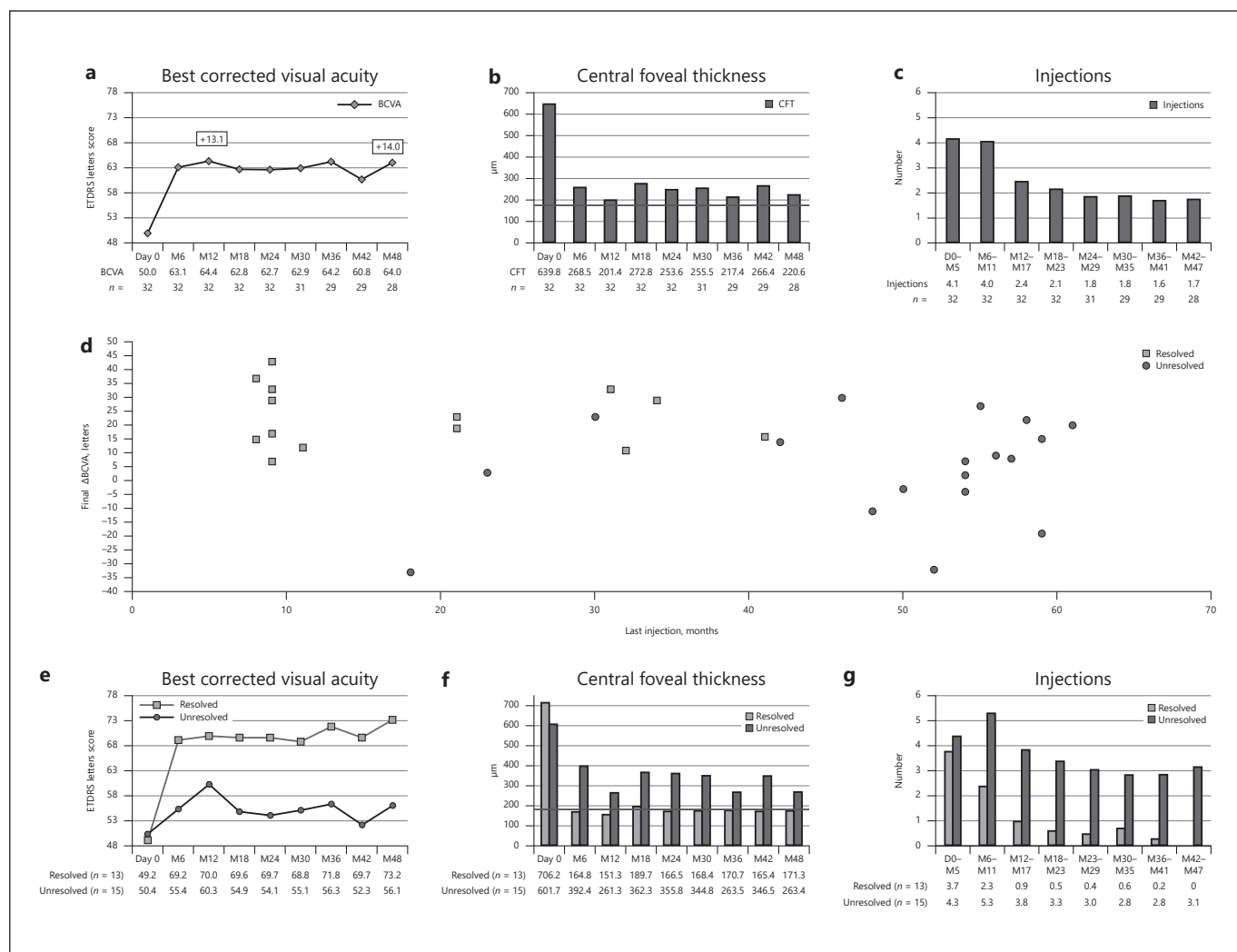
Resolution of macular edema was defined as the absence of IRF and SRF in the macula for at least 6 months after the last injection of ranibizumab. It occurred in 50% of patients with BRVO who entered the RETAIN study; however, the amount of improvement in BCVA at the last visit was not significantly greater for patients with resolved than with unresolved edema (25.9 vs. 17.1 letters;  $p = 0.09$ ). Unlike patients with BRVO, those with CRVO who had a resolution of edema (43.8%) had a superior visual outcome compared with those who did not (73.2 vs. 56.1 letters;  $p = 0.01$ ). RETAIN study patients who re-

ceived grid laser photocoagulation did not differ statistically significantly in visual outcome; neither did they show a greater reduction in mean CRT nor did they require fewer injections of ranibizumab. Patients with BRVO or CRVO who did not have a resolution of edema had a higher mean age and were statistically significantly more likely than patients whose edema resolved to have arterial hypertension. These data indicate that functional outcome was maintained after 4 years of a PRN regimen with ranibizumab injections in CRVO with a reduced number of injections compared with the observation period of the BRAVO study. Also it is evident that in a long-term follow-up, patients with CRVO or BRVO will still require ranibizumab injections to control edema [56, 57].

#### Dosing and Regimen

**0.5 mg versus 2.0 mg Ranibizumab.** 0.5 and 2.0 mg ranibizumab were compared in the RELATE (Ranibizumab Dose Comparison (0.5 and 2.0 mg) and the Role of Laser in the Management of Retinal Vein Occlusion) Study, a double-masked, randomized, controlled clinical trial with 24 weeks of monthly injections, followed by re-randomization to two PRN arms for recurrent edema, on prespecified OCT-based criteria: ranibizumab plus laser or ranibizumab alone. Patient populations differed from those in BRAVO and CRUISE because they were not treatment naïve and were not excluded for duration of disease of 1 year or more [49]. Patients with BRVO showed a rapid reduction in mean CRT at 1 month, with little change thereafter and no statistically significant difference between groups at week 24 ( $p = 0.19$ ). In patients with CRVO, the initial reduction in mean CRT was greater in those treated with 2.0 mg ranibizumab, and a significant difference remained at week 24 (mean CRT improvement  $-253.5 \mu\text{m}$  in the 0.5 mg ranibizumab group vs.  $-396.1 \mu\text{m}$  in the 2.0 mg ranibizumab group,  $p = 0.03$ ). However, injections with 0.5 mg ranibizumab were sufficient to achieve similar functional improvement (mean BCVA change from baseline was +12.1 and +14.6 letters in the 0.5 and 2.0 mg ranibizumab groups, respectively,  $p = 0.31$ , in patients with BRVO, and +15.5 and +15.8 letters,  $p = 0.94$ , in patients with CRVO, at week 24), showing no clinically significant benefit in using 2.0 mg ranibizumab [49].

At the secondary endpoint (2.5 years after randomization), there was no significant difference in CRT or BCVA mean change from week 24 in ranibizumab plus laser groups versus ranibizumab only groups, as well as in the mean number of PRN ranibizumab injections and the number of patients whose edema resolved. These data



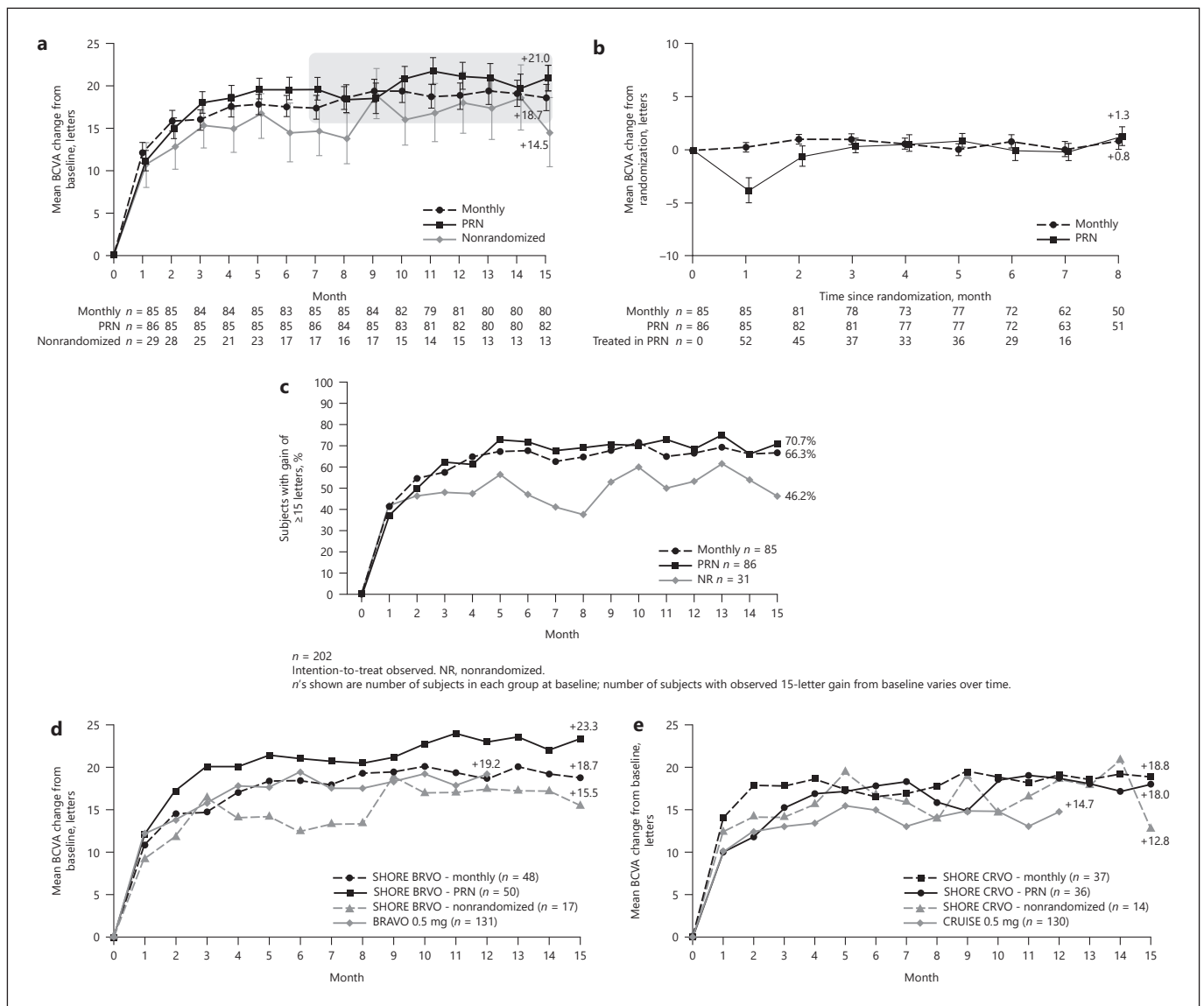
**Fig. 12.** The RETAIN Study. Graphs showing that patients with central retinal vein occlusion treated with ranibizumab have good long-term outcomes. **a** Mean best-corrected visual acuity (BCVA) in Early Treatment Diabetic Retinopathy Study (ETDRS) letter score plotted at 6-month intervals from first entry into the Ranibizumab for the Treatment of Macular Edema after Central Retinal Vein Occlusion Study: Evaluation of Efficacy and Safety (CRUISE) study. **b** Mean CFT (center point thickness by Stratus optical coherence tomography [Carl Zeiss Meditec Inc., Dublin, CA, USA]) plotted at 6-month intervals from first entry into CRUISE. Dark gray line represents a value of 172 μm, the mean CFT reported in normal patients. **c** Mean number of injections per 6-month inter-

val from first entry into CRUISE. **d** Final change in BCVA (ΔBCVA) plotted against the time after CRUISE baseline when the last injection of ranibizumab was given for resolved patients (no edema for at least 6 months after last injection of ranibizumab [gray squares] and unresolved patients [black circles]). **e** Mean BCVA plotted at 6-month intervals for resolved patients (gray squares) vs. unresolved patients (black circles). **f** Mean CFT plotted at 6-month intervals for resolved (gray) vs. unresolved (black) patients. Dark gray line represents a value of 172 μm, the mean CFT reported in normal patients. **g** Mean number of injections per 6-month interval for resolved (gray) vs. unresolved (black) patients [56].

confirmed previous data for patients with BRVO and with CRVO [45, 49].

**Ranibizumab versus Bevacizumab Treatment.** With regard to the different treatment regimens, several studies are available. The MARVEL (Macular Edema due to Branch Retinal Vein Occlusion) Study evaluated the ef-

ficacy of intravitreal 0.5 mg ranibizumab and 1.25 mg bevacizumab in patients affected by macular edema secondary to BRVO (for details, see the section Bevacizumab). Taken together, the mean number of injections in the MARVEL trial was statistically significantly less than that seen in the BRAVO trial at 6 months (3 vs. 6, respec-



**Fig. 13.** The SHORE Study. Graphs showing observed visual outcomes. **a** Mean improvement from baseline best-corrected visual acuity (BCVA) in Early Treatment Diabetic Retinopathy Study (ETDRS) letter score. **b** Mean improvement from randomization BCVA in ETDRS letter score (randomized patients only). **c** Percentage of patients who experienced a gain from baseline ETDRS

letter score of 15 or more. **d, e** Visual gains in patients with branch retinal vein occlusion (BRVO) and central retinal vein occlusion (CRVO), respectively. BRAVO, Branch Retinal Vein Occlusion: Evaluation of Efficacy and Safety; CRUISE, Central Retinal Vein Occlusion Study: Evaluation of Efficacy and Safety; NR, non-randomized; PRN, pro re nata (as needed) [61].

tively) and from 6 to 12 months (0.29 vs. 2.7, respectively). The anatomic outcome at 6 and 12 months showed an apparent greater improvement in the BRAVO study with a monthly injection regimen ( $-345.2$  and  $-347.4$   $\mu\text{m}$  at 6 and 12 months, compared with  $-177.1$  and  $-165.7$   $\mu\text{m}$  in the MARVEL study) but still achieved a comparable VA result at month 6 [46, 47, 59, 60]). The percentage of patients who obtained a Snellen equivalent  $\geq 20/40$  at

month 12 was 62.16% in the MARVEL study versus 66.4% in the BRAVO study [46, 60].

*Fixed Monthly versus PRN Treatment of Ranibizumab.* A direct comparison of monthly versus PRN regimen was made in the SHORE Study (Evaluating Dosing Regimens for Treatment with Intravitreal Ranibizumab Injections in Subjects with Macular Edema following Retinal Vein Occlusion), a 15-month, phase IV, multicenter, random-



ized trial evaluating the efficacy and safety of monthly versus PRN injections of 0.5 mg ranibizumab in patients with macular edema after BRVO or CRVO diagnosed within 12 months of screening and who had received at least 7 injections 1 month apart and met VA and OCT stability criteria at some visit between months 7 and 14 [61]. At month 15, the percentage of patients who had a gain of  $\geq 15$  letters from baseline was 66.3% in the monthly group and 70.7% in the PRN group. The percentage of patients with BCVA  $\geq 20/40$  was nearly identical in the two randomization groups throughout the entire study period, and at month 15 it was 71.3% in the monthly group and 76.8% in the PRN group. None of these responses were significantly different between the two groups ( $p > 0.05$ ) (Fig. 13). Moreover, despite a slightly higher percentage of macular edema in the PRN group (32.9%) than in the monthly group (25.0%) ( $p = 0.301$ ), the PRN group showed a significantly larger BCVA improvement over the monthly group at month 15 ( $p = 0.048$ ).

During the 8-month alternate-dose period, the number of injections was approximately half in the PRN group (7.6 and 3.7 for the monthly and the PRN group, respectively), but there was considerable heterogeneity among patients. Patients who did not achieve stability criteria to be randomized showed a similar improvement in BCVA as the randomized patients during the first 3 months of the trial but then deteriorated despite monthly injections. This suggests that these patients, even if few, represent a distinct population who have a less sustained or less robust response, or both, to ranibizumab [61].

The similar outcomes in patients treated with monthly injections for 15 months versus those switched to PRN after stabilization may indicate that recurrence of edema after stabilization does not adversely affect VA outcomes, at least up to 15 months. However, other studies have suggested that on average patients with CRVO are more likely than those with BRVO to experience increased edema and reduced vision when the duration between follow-up visits is increased [56, 57].

The heterogeneity among SHORE patients highlights the potential clinical value of a period of PRN treatment to identify patients for whom the number of treatments can be successfully reduced [61].

*Individualized Treatment and Combination.* The CRYSTAL and BRIGHTER trials assessed the efficacy and safety of an individualized dosing regimen of 0.5 mg ranibizumab driven by VA stabilization criteria (defined as three consecutive visits with stable VA) in 357 and 455 patients with visual impairment resulting from macular

edema secondary to CRVO and BRVO, as recommended in the European Summary of Product Characteristics [16, 17, 62, 63].

The 12-month CRYSTAL study results showed a significant mean gain in BCVA from baseline for patients with CRVO with a mean of 9.1 injections (+12.3 letters,  $p < 0.0001$ ), occurring rapidly after the first injection (+8.9 letters,  $p < 0.0001$ ). A 15-letter gain was obtained in 49.2% of the patients and 47.5% attained a BCVA of 20/40 at month 12. A stable VA was achieved in 37% of patients after the three initial mandatory injections [16]. The BRIGHTER study confirmed the long-term efficacy of PRN dosing driven by individualized VA stabilization criteria in patients with BRVO, showing no statistically significantly better functional outcomes or lower treatment need when adding laser photocoagulation (+15.5 and +17.3 letters for ranibizumab and ranibizumab plus laser, respectively, at month 24, with 11.4 and 11.3 injections) [17].

Moreover, differing from most previous studies, these studies analyzed a broad population including patients with various degrees of retinal ischemia and disease duration. Nevertheless, statistically significant BCVA gains from baseline resulted, regardless of the baseline BCVA score, CRVO duration, or degree of ischemia at baseline. However, as in the BRAVO study, the mean BCVA gain from baseline was higher in patients with a lower than in those with a higher baseline BCVA (ceiling effect) and with a shorter duration of RVO at baseline than those with a longer one [16, 17, 63].

Most studies evaluating progression of retinal and iris neovascularization secondary to BRVO showed no or rare cases of these complications both in ranibizumab- and laser-treated patients, even when the studies with longer follow-up admitted rescue anti-VEGF injections after their first period of sham [17, 45, 46, 59]. Conversely, in the CRUISE and CRYSTAL studies, the incidence of iris neovascularization and neovascular glaucoma was higher in the sham than in the ranibizumab groups. However, they were reported to occur in a small percentage of patients with CRVO, despite ranibizumab therapy [16, 58].

### Recommendation

Several randomized, controlled studies have proven the efficacy and safety of ranibizumab in macular edema secondary to RVO. An individualized dosing regimen of 0.5 mg ranibizumab, driven by VA stabilization criteria, as recommended by the European Summary of Product Characteristics, has been shown to provide anatomic and functional improvement in both BRVO and CRVO

with obvious higher final VA achieved in BRVO [16, 17, 59, 62, 64–66].

Moreover, data on patients with longer disease duration suggest the necessity for prompt intravitreal treatment, as also proven by the inferior results in patients injected after a first laser-only period compared with patients injected early [16, 17, 46, 58, 63]. Subsequent monthly injections must be continued until VA stability is reached. Long-term data support a monthly follow-up period for at least 1 year, with subsequent extension upon functional and/or anatomic stability reducing the treatment burden while maintaining functional stability [56, 57]. In fact, it has been proven that although ranibizumab monthly injections suppress the effects of VEGF in most patients, they did not eliminate VEGF production, as shown by the reduction of visual and anatomic benefits at injection interruption points [46, 58]. In addition, cases of late recurrence in the RETAIN study verified the importance of long-term follow-up, particularly in patients with CRVO. First year follow-up also has the relevant role of allowing individualized treatment for less responsive patients and patients with VA more susceptible to edema persistence or recurrence. Therefore, treatment regimens need to be fitted to each patient's needs [56].

### *Aflibercept*

#### **Rationale**

Aflibercept, formerly known as VEGF trap-eye, is a receptor fusion protein of key domains from human VEGF receptors 1 and 2 with the constant region (Fc) of human immunoglobulin G that binds to multiple isoforms of VEGF-A, VEGF-B, and placental growth factor [55]. It has shown efficacy and safety in adequate clinical trials in AMD and DME [48]. In preclinical studies, the binding affinity of aflibercept for VEGF was shown to be greater than that of either bevacizumab or ranibizumab, and its duration of action in the eye is theoretically longer [48, 49, 55, 67].

#### **Evidence**

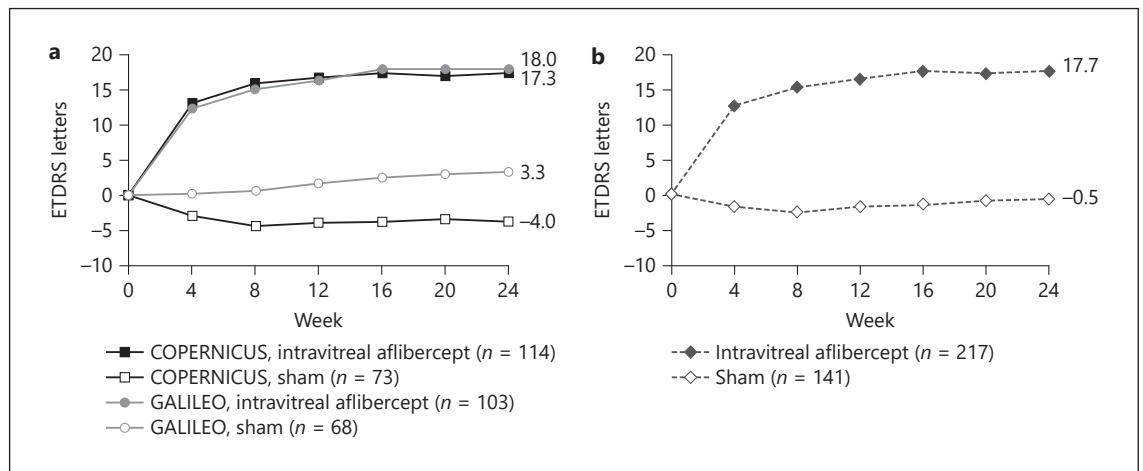
##### *Central Retinal Vein Occlusion*

The COPERNICUS and GALILEO Studies (Vascular Endothelial Growth Factor Trap-Eye: Investigation of Efficacy and Safety in Central Retinal Vein Occlusion) were two parallel randomized, double-masked, phase III studies that every 4 weeks compared intravitreal 2 mg aflibercept with sham treatment of macular edema secondary to CRVO, diagnosed within 9 months in treatment-naïve patients. From week 24 to week 52, all intravitreal aflibercept-treated patients in both studies and sham-treated

patients in COPERNICUS were eligible to receive intravitreal aflibercept on prespecified OCT and VA criteria (PRN). Sham-treated patients in GALILEO were eligible to receive intravitreal aflibercept only after week 52 [55]. At week 24, the mean change in CRT from baseline was  $-453.1\ \mu\text{m}$  in the intravitreal aflibercept group and  $-157.2\ \mu\text{m}$  in the sham group. At week 52, the mean change in CRT from baseline was  $-418.0\ \mu\text{m}$  in the intravitreal aflibercept group,  $-381.8\ \mu\text{m}$  in the sham-aflibercept group, and  $-219.3\ \mu\text{m}$  in the sham group.

At week 24, mean BCVA change from baseline was  $+17.7$  and  $-0.5$  letters in the aflibercept and the sham group, respectively (15-letter BCVA gain from baseline in 60.4 and 17.0% of the aflibercept and the sham group, respectively,  $p < 0.001$ ) (Fig. 14). Between week 24 and 52, mean BCVA gain from baseline was maintained for aflibercept;  $+7.8$  and  $+0.5$  letters were gained in the sham-aflibercept (COPERNICUS) and the sham group (GALILEO), respectively. Switching from monthly to PRN regimen at 6 months resulted in a smaller functional decline compared with the same period in the CRUISE study, confirming a longer duration of effect with aflibercept (Fig. 14). The mean number of injections received in the intravitreal aflibercept group from baseline to week 24 was 5.8. From week 24 to 52, it was 2.6 in the aflibercept group, 3.9 in the sham/aflibercept group and 0 in the sham group. In the second period, patients who received delayed injections achieved a lower VA outcome than those in the aflibercept group despite their higher number of injections [55]. Moreover, a higher proportion of patients who received aflibercept  $< 2$  months after diagnosis gained  $> 15$  letters at 52 weeks compared with those who received treatment  $> 2$  months after diagnosis [68]. From week 52, patients were monitored every 8 weeks (GALILEO) or quarterly (COPERNICUS), and both groups received intravitreal aflibercept PRN. The visual and anatomic gains decreased during the second year with PRN dosing and extended follow-up, suggesting that more frequent monitoring may be necessary to prevent disease recurrence [69, 70]. Analysis of subgroups showed a marked improvement in BCVA with aflibercept in patients with non-perfused retinas ( $> 10$  disc areas of retinal capillary non-perfusion on FA) at baseline, in contrast to a particularly poor response in the sham group [71].

The results of the integrated analysis of COPERNICUS and GALILEO were consistent with the generally favorable safety profile of intravitreal aflibercept. The serious adverse events observed in this study largely comprised adverse events attributable to underlying disease(s). Moreover, eyes treated with aflibercept showed a lower



**Fig. 14.** The CERNICUS and GALILEO Studies. Mean change in best-corrected visual acuity for (a) CERNICUS and GALILEO and (b) an integrated data set from baseline to week 24 (last observation carried forward). ETDRS, Early Treatment Diabetic Retinopathy Study [55].

trend to progress to any (retina and iris) neovascularization compared with the sham groups [55]. A few cases of optic disc and iris neovascularization appeared after week 52 with longer follow-up intervals, confirming the necessity for more frequent monitoring [69, 71].

Based on the results of the CERNICUS and GALILEO Studies, intravitreal aflibercept was approved in the US (in 2012) by the FDA and in Europe (2013) by the EMA for treatment of macular edema due to CRVO.

#### Branch Retinal Vein Occlusion

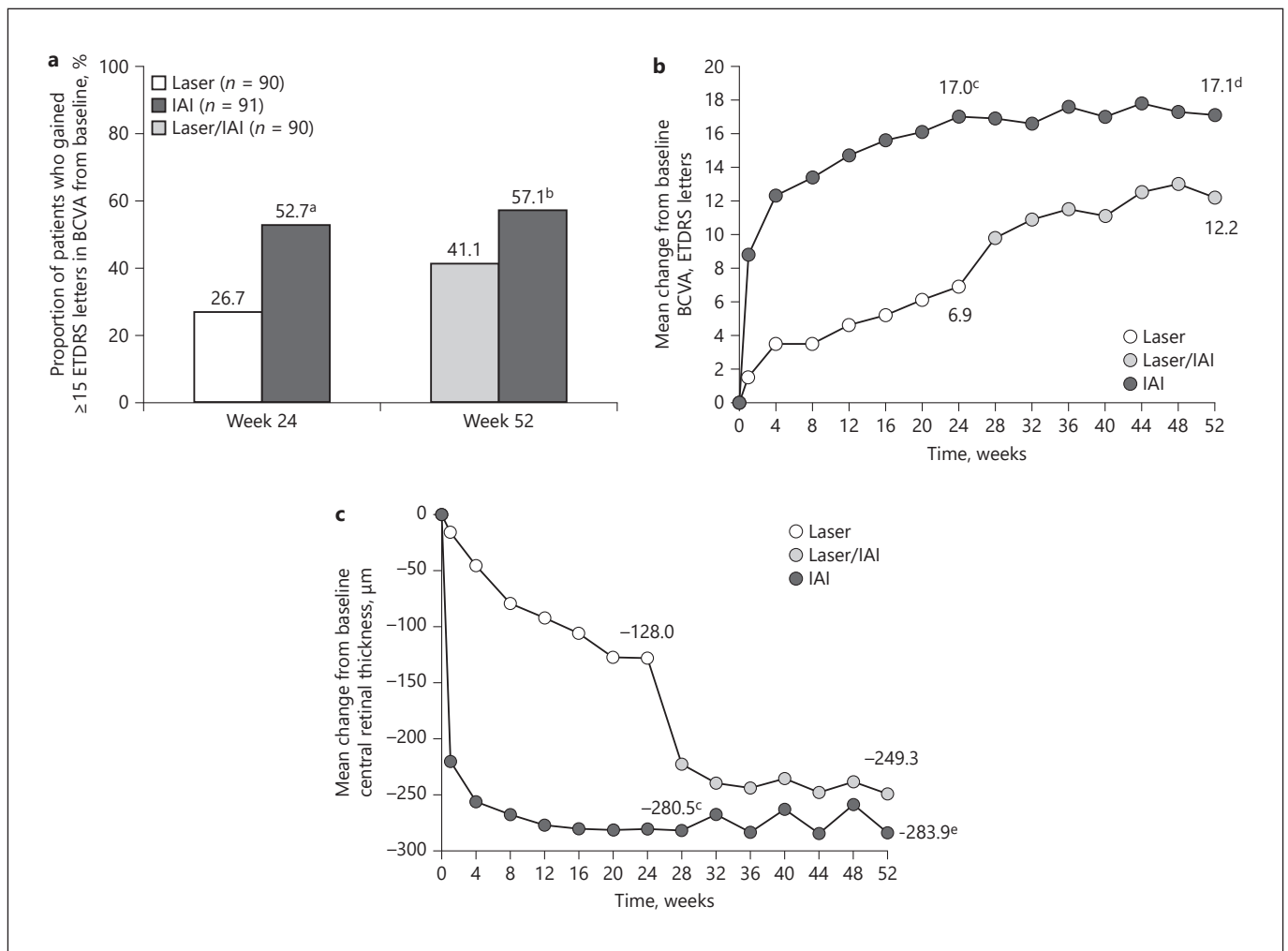
With regard to BRVO, the VIBRANT Study (to Assess the Clinical Efficacy and Safety of Intravitreal Aflibercept Injection (EYLEA®; BAY86-5321) in Patients with Branch Retinal Vein Occlusion), a phase III, multicenter, randomized, double-masked, active-controlled, 52-week trial, compared the efficacy and safety of 2 mg intravitreal aflibercept with macular grid laser photocoagulation for treatment of macular edema after BRVO, diagnosed within 12 months. Eyes in both treatment groups were evaluated for rescue treatment from week 12 onwards based on prespecified criteria. Eyes in the aflibercept group received an injection every 4 weeks from baseline to week 20 and then every 8 weeks from week 24 to week 48 with sham injections in between. Eyes in the laser group received aflibercept injections (3 monthly injections followed by every 8 weeks) as rescue treatment if prespecified VA and OCT criteria were met [49].

At week 24, the aflibercept group was significantly superior to the laser group in functional outcome (mean

BCVA change from baseline +17 compared with +6.9 letters ( $p < 0.0001$ ); a 15-letter BCVA gain from baseline in 52.7% compared with 26.7% ( $p = 0.0003$ ) (Fig. 15). Mean BCVA improvement was significantly greater for patients with worse BCVA at baseline (+15.7 vs. +6.9 in eyes with baseline BCVA  $>20/200$  and +34.5 vs. +7.3 in eyes with baseline BCVA of  $\leq 20/200$ ,  $p < 0.0001$  and  $p = 0.0168$ , respectively) [49]. At week 24, the mean change in CRT from baseline was  $-280.5 \mu\text{m}$  in the aflibercept group compared with  $-128.0 \mu\text{m}$  in the laser group ( $p < 0.0001$ ) [49] (Fig. 15). The rescue criteria were met in 80.7% of laser-treated eyes, which were then injected with an average of 4.4 injections from week 24 to 52. At week 52, anatomic and visual outcomes were maintained in the aflibercept group with extended interval injections (and rescue grid laser given in approximately 10% of eyes) [49]. Visual improvement in the laser group was, however, still statistically significantly inferior to the aflibercept group. No significant difference between perfused and non-perfused eyes was reported at week 52 [48]. The percentage of eyes with a VA  $\geq 20/40$  in the aflibercept and the laser group was 24.2 and 18.9% ( $p = 0.3910$ ) at baseline, 82.4 and 46.7% ( $p < 0.0001$ ) at week 24, and 84.6 and 67.8% ( $p = 0.0054$ ) at week 52 [48, 49].

The proportion of eyes with perfused retinas in the aflibercept and laser groups was 60.4% versus 68.9% at baseline, 80.2% versus 67.1% ( $p = 0.0497$ ) at week 24, and 77.9% versus 78.0% ( $p = 0.7742$ ) at week 52, respectively. Therefore, between weeks 24 and 52, when the laser group





**Fig. 15.** The VIBRANT Study. Visual and anatomic outcomes. The percentage of eyes that gained  $\geq 15$  in letter score from baseline to weeks 24 and 52 (**a**), and the mean change from baseline in best-corrected visual acuity (BCVA) (**b**) and central retinal thickness (**c**) over 52 weeks are shown. Full analysis set. Missing data were imputed using the last observation carried forward method. <sup>a</sup>  $p = 0.0003$ , <sup>b</sup>  $p = 0.0296$ , <sup>c</sup>  $p < 0.0001$ , <sup>d</sup>  $p = 0.0035$ , and <sup>e</sup>  $p = 0.0218$  vs. laser. ETDRS, Early Treatment Diabetic Retinopathy Study; IAI, intravitreal aflibercept injection [48].

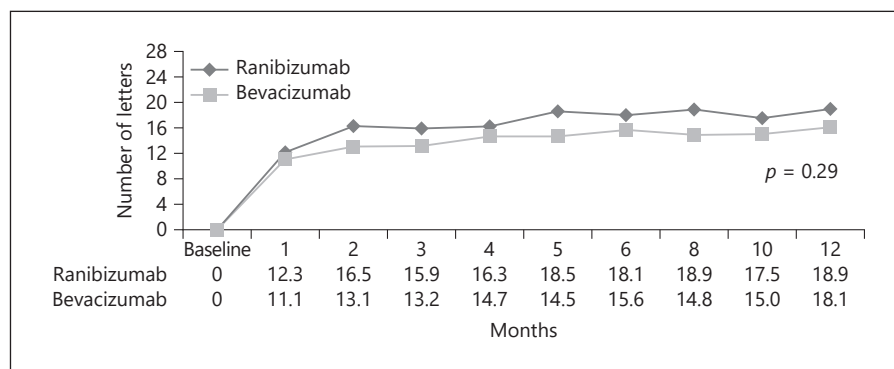
received treatment with intravitreal aflibercept as well, the between-group difference in retinal non-perfusion became non-significant [48]. During the 52 weeks of the study, 4 cases of retinal neovascularization, all in the laser group, and no case of anterior segment neovascularization were reported [48]. Non-ocular severe adverse events occurred with a similar frequency in the aflibercept and laser groups during the study [49].

Intravitreal 2 mg aflibercept was approved for treatment of macular edema due to BRVO by the FDA in 2014 and by the EMA in 2015.

## Recommendation

Intravitreal aflibercept has proven to be effective in the treatment of macular edema secondary to RVO. Early treatment is important for optimal outcomes. After fixed initial monthly injections, visual gain can largely be maintained, including regimens with extended intertreatment intervals [68, 71–73]. The PRN regimen in the COPERNICUS and GALILEO studies demonstrated a sustained efficacy at 1 year in patients with CRVO [68, 71]. In the VIBRANT study, the switch to bimonthly treatment in patients with BRVO was shown to preserve visual outcomes, reducing the treatment burden [48].

**Fig. 16.** The MARVEL Study. Gain in letters from baseline to 1 year comparing ranibizumab and bevacizumab. Data points represent the mean gain in best-corrected visual acuity [60].



A multicenter study (CENTERA) is on-going to evaluate a treat-and-extend regimen of aflibercept in macular edema secondary to CRVO. In any case, long-term close monitoring is advisable to control macular edema, particularly in patients with CRVO, probably because of the continued excessive production of VEGF due to retinal ischemia [69, 70]. Moreover, as in previous ranibizumab studies, aflibercept therapy was shown to be also effective in reducing non-perfused retinal areas as well as posterior and anterior segment neovascularization when patients are monitored adequately [68, 72].

#### Bevacizumab

##### Rationale

Bevacizumab is a full-length, humanized, recombinant, monoclonal antibody that binds to and inhibits VEGF-A [59, 67]. The molecule was developed to inhibit pathological tumor vessel formation and tumor growth in metastatic colon cancer. Intraocular bevacizumab is widely used as an off-label treatment for neovascular AMD and DME, and costs less than ranibizumab and aflibercept [67]. The standard dose of intraocular bevacizumab when used for ocular disease is 1.25 mg in 0.05 mL. In randomized comparison trials, bevacizumab was found to be non-inferior to ranibizumab for the treatment of AMD and DME [59], although the treatment of choice in DME is more complex after the results of the Diabetic Retinopathy Clinical Research Network Protocol T comparative trial [19].

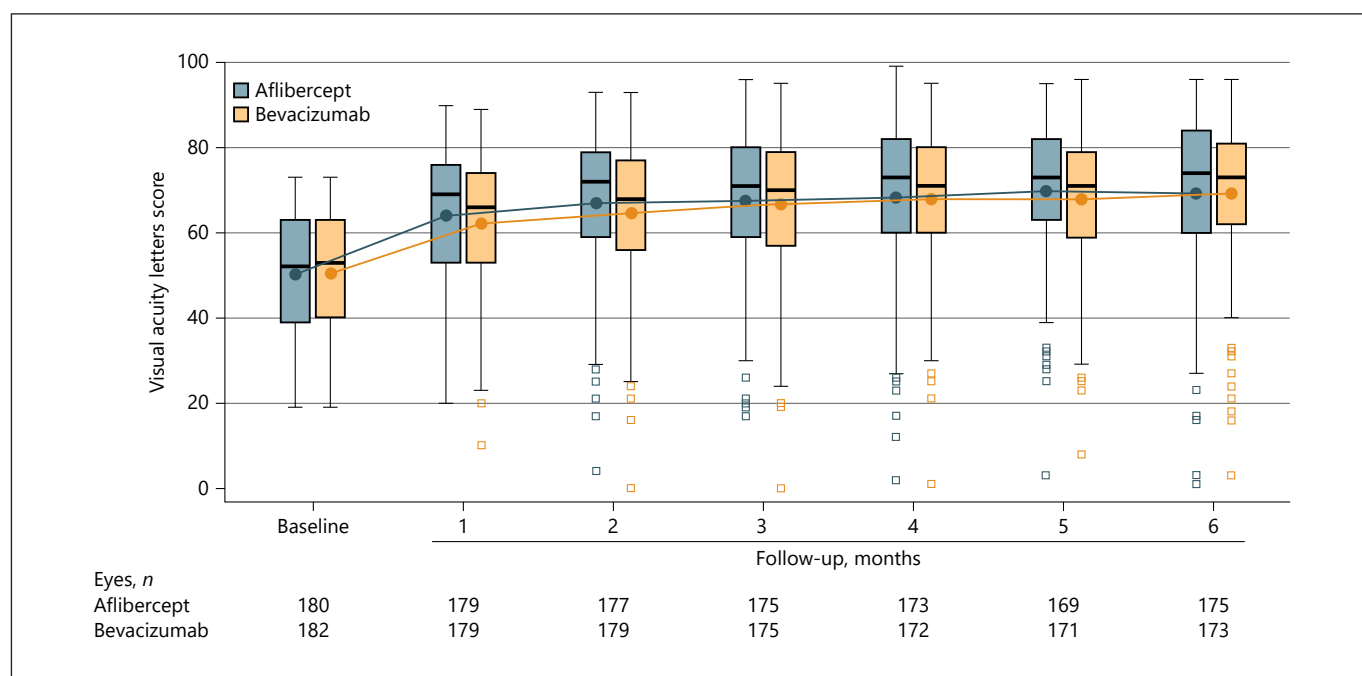
##### Evidence

The MARVEL study, as described above, was a randomized, double-masked, prospective, non-inferiority trial that compared intravitreal 0.5 mg ranibizumab and 1.25 mg bevacizumab in 75 patients with macular edema due to BRVO of less than 9 months duration. Patients

were evaluated monthly for 6 months and bimonthly for the following 6 months and treated on a PRN basis. At month 6, no significant difference between treatment groups in functional outcome was reported (mean BCVA change from baseline +18 and +15.6 letters for the ranibizumab and the bevacizumab arm, respectively,  $p = 0.74$ ; 15-letter BCVA gain from baseline in 59.4 and 57.8% of the ranibizumab and bevacizumab arm, respectively,  $p = 1.0$ ). 43.2 and 42.1% of the ranibizumab- and bevacizumab-treated patients gained more than 15 letters after the first injection (Fig. 16). The percentage of patients who obtained a Snellen equivalent of  $>20/40$  at month 6 was 62.2% in the ranibizumab and 68.4% in the bevacizumab group [59]. The VA difference of  $-2.5$  letters between groups was not enough to reach the non-inferiority limit (5 letters) because of the large variance in VA changes (CI from  $-8.0$  to  $+5.0$  letters). At month 6, the mean change in CRT from baseline was  $-177.1$  and  $-201.7 \mu\text{m}$  in the ranibizumab and the bevacizumab group ( $p = 0.30$ ). 10.8% of patients receiving ranibizumab required rescue laser compared with 21.0% of patients receiving bevacizumab ( $p = 0.34$ ). The mean PRN number of injections was 3.2 and 3.0 for ranibizumab and bevacizumab, respectively [59].

The visual benefits of PRN bevacizumab and ranibizumab were sustained at the 12-month secondary end-point, with a final VA of  $\geq 20/40$  in 62.16% of the ranibizumab-treated and in 65.78% of the bevacizumab-treated eyes ( $p = 0.8$ ). The non-inferiority of bevacizumab still could not be demonstrated ( $-2.8$  letters; 95% CI  $-7.0$  to  $+4.0$  letters) [60] (Fig. 16). Two patients in both groups developed retinal neovascularization [59].

The SCORE2 Study (Study of Comparative Treatments for Retinal Vein Occlusion 2) was a multicenter, randomized clinical trial that investigated the non-inferiority of 1.25 mg bevacizumab to 2.0 mg aflibercept, ad-



**Fig. 17.** The SCORE2 Study. The center horizontal line of each box indicates the median; circle, mean; and top and bottom borders of each box, 75th and 25th percentiles, respectively. The whiskers extend to the minimum observation above the lower fence and maximum observation below the upper fence, which are defined as 1.5 times the interquartile range below the 25th percentile and above the 75th percentile, respectively. The outliers (squares) mark any observation below the lower fence or above the upper fence [67].

ministered monthly for 6 months to 362 patients with macular edema due to central retinal or hemiretinal vein occlusion, some treatment-naïve and others not. At month 6, bevacizumab was non-inferior to aflibercept based on a margin of 5 ETDRS letters. Mean BCVA gain was +18.9 and +18.6 in the aflibercept and the bevacizumab group, respectively, with a  $\geq 10$ -letter gain already at month 1. 65.1% of the patients in the aflibercept group gained  $\geq 15$  letters at month 6 compared with 61.3% in the bevacizumab group ( $p = 0.89$ ). In a post hoc analysis, the number of eyes achieving a VA  $\geq 20/40$  at month 6 was 57.7% in the aflibercept group and 57.2% in the bevacizumab group ( $p = 0.89$ ) [67]. In a univariate analysis, shorter macular edema duration prior to therapy was associated with a greater VA gain as also previously reported in the GALILEO and COPERNICUS studies. Moreover, the multivariate analysis showed younger age and lower baseline VA to be factors associated with greater VA gain, as previously reported in the COPERNICUS study and similar to the anti-VEGF treatment response in DME. Both groups showed a statistically significant CRT decrease from baseline through month 6 with a mean reduction of  $-425 \mu\text{m}$  in the aflibercept group and  $-387 \mu\text{m}$

in the bevacizumab group ( $p = 0.83$ ). At month 6, 54.4% of eyes in the aflibercept group had a resolution of macular edema compared with 28.5% in the bevacizumab group ( $p < 0.001$ ), with no influence on functional outcomes [67, 74] (Fig. 17).

Post hoc analyses showed that factors associated with favorable OCT outcomes were aflibercept treatment, no prior anti-VEGF treatment, and higher baseline CRT (probably because of a higher potential of reduction than lower CRT), consistent with results of the Diabetic Retinopathy Clinical Research Network Protocol T. Previous anti-VEGF treatment could signify worse disease, which was already refractory to anti-VEGF therapy and which, therefore, may be more likely to be refractory to additional anti-VEGF treatment [74].

Rates of adverse events were similar for both drugs and consistent with those reported in other phase III trials evaluating anti-VEGF therapy for RVO, AMD, and DME [67].

### Recommendation

Bevacizumab proved to effectively reduce macular thickness in these comparative, non-inferiority trials and

to improve VA in patients with macular edema due to RVO using both monthly and PRN regimens. A very high gain of ETDRS letters was obtained after the first injection compared with AMD and DME [59, 67].

The non-inferiority of bevacizumab to ranibizumab in CRVO was found in the SCORE2 study with a monthly regimen despite less reduction in CRT in the bevacizumab than in the ranibizumab group; longer follow-up with an eventual switch to PRN could confirm this result [67]. The large range of BCVA results in patients with BRVO in the MARVEL study did not reach the non-inferiority limit, but the regimen of treatment was different from the SCORE2 Study, and the population was smaller [59, 60]. The PRN regimen with bimonthly evaluations after the first 6 months of the MARVEL study may have reduced the treatment burden, but because of the limited number of patients and short follow-up, further studies are required to confirm these data [60].

Post hoc analysis of the SCORE2 trial confirmed previous data obtained with other anti-VEGF drugs showing better visual results in shorter duration macular edema, younger patients and lower BCVA at baseline with no statistically significant disparity between groups treated with different drugs [74]. This supports the necessity for an individualized approach to each patient, based on baseline features and treatment response.

## **Steroids**

### **Rationale**

The pathogenesis of RVO (both CRVO and BRVO) involves an increase in capillary permeability that results in macular edema as well as raised venous pressure and hypoxia. This is caused by a breakdown of the blood-retina barrier mediated in part by VEGF and in part by inflammatory cytokines [54]. Although the mean vitreal levels of VEGF are elevated in both disease states (CRVO and BRVO) in one-third of the eyes, these may fall within the normal range despite the presence of macular edema [75–77]. This finding indicates the existence of VEGF-independent pathways leading to macular edema that may be the reason why some patients are less responsive to anti-VEGF therapy alone.

The rationale for the use of steroids to treat macular edema is related to their ability to reduce capillary permeability. Steroids inhibit the expression of the VEGF gene and the metabolic pathways of VEGF, and, in addition, that of inflammatory cytokines [78, 79]. Additionally, corticosteroids may also have a neuroprotective effect that is beneficial in eyes with RVO [80]. Several proinflammatory mediators, mostly cytokines such as TNF $\alpha$ ,

IL-1, MCP-1, and IL17-E, have been shown to be involved in macular edema secondary to RVO [81–83]. Another interesting rationale for the use of steroids in RVO was suggested by a recent study that showed an increase in the arteriovenous oxygen saturation difference measurement in patients with RVO, indicating improved retinal oxygenation following Ozurdex<sup>®</sup> injection [84].

### **Evidence**

Commercially available corticosteroid compounds for intravitreal use include triamcinolone acetonide, dexamethasone posterior segment delivery system (Ozurdex<sup>®</sup>), and fluocinolone implant (Iluvien<sup>®</sup>). Fluocinolone has not been investigated thoroughly for RVO and is not therefore discussed here.

#### *Triamcinolone Acetonide*

The first steroid to be used intravitreally was triamcinolone as a readily available pharmacologic agent (Kenalog 40, Bristol-Myers Squibb, Princeton, NJ, or Triescence, Alcon Inc., Fort Worth, TX, USA), although its use for the treatment of macular edema is off-label. Other formulations such as compounded preservative-free triamcinolone acetonide are also used in the clinical setting.

Triamcinolone acetonide has been used for many years and reported to be efficient in many pilot trials [79]. The most comprehensive trial investigating triamcinolone acetonide for the treatment of RVO was the SCORE (Standard Care vs. Corticosteroid for Retinal Vein Occlusion) trial.

The SCORE-BRVO trial was a multicenter clinical trial which compared the efficacy and safety of 1 and 4 mg doses of preservative-free intravitreal triamcinolone (Trivaris; Allergan) with the standard of care (grid photocoagulation in eyes without dense macular hemorrhage, and deferral of photocoagulation until hemorrhage clears in eyes with dense macular hemorrhage) for eyes with vision loss associated with macular edema secondary to BRVO. The drug used in this trial was prepared as a sterile, preservative-free, single-use intravitreal injection with 1 and 4 mg doses in a volume of 0.05 mL. The SCORE trial identified no difference in VA at 12 months between the standard care and the triamcinolone groups; however, rates of adverse events (particularly elevated IOP and cataract) were highest in the 4 mg group [85]. It is possible that the VA results in the treated group were somewhat biased because of the high percentage of cataract progression in this group. The authors stated that grid photocoagulation as applied in the SCORE study has remained the standard of care for patients with vision loss associ-



ated with macular edema secondary to BRVO who present similar characteristics to those patients in the SCORE-BRVO trial. In a subgroup analysis of the SCORE-BRVO trial, those patients with a disease duration <3 months showed a trend towards greater benefit than the standard of care group. However, of those patients with macular edema for >3 months, 34% in the 4 mg group showed a gain of 15 letters or more versus 15% in the standard of care group. Although not statistically significant, this indicates how important it is to take the duration of edema into account when analyzing data and when comparing the results of different trials, which may differ in baseline characteristics.

The SCORE-CRVO trial was a multicenter clinical trial which compared the efficacy and safety of 1 mg and 4 mg doses of preservative-free intravitreal triamcinolone (Trivaris; Allergan) with the standard of care (observation) for eyes with vision loss associated with macular edema secondary to non-ischemic CRVO. Drug preparation was similar to the one used in the SCORE-BRVO trial. The SCORE trial concluded that intravitreal triamcinolone is superior to observation for treating vision loss associated with macular edema secondary to CRVO in patients who have characteristics similar to those in the SCORE-CRVO trial. Seven percent of participants in the observation, 27% in the 1 mg, and 26% in the 4 mg group achieved the primary outcome (at least 15 letters of improvement in VA on an ETDRS chart). The odds of achieving the primary outcome were five times greater in the 1 mg than in the observation group (odds ratio (OR) 5.0; 95% CI, 1.8–14.1;  $p = 0.001$ ) and five times greater in the 4 mg than the observation group (OR, 5.0; 95% CI, 1.8–14.4;  $p = 0.001$ ); there was no difference identified between the 1 and 4 mg groups (OR, 1.0; 95% CI, 0.5–2.1;  $p = 0.97$ ). The rates of elevated IOP and cataract were similar for the observation and 1 mg groups, but higher in the 4 mg group. Based on these results, the authors stated that triamcinolone acetonide should become the standard of care for patients with vision loss associated with macular edema secondary to CRVO who present with similar characteristics as patients in the SCORE-CRVO trial [85]. It should be noted that there is no evidence suggesting that the visual and anatomic responses achieved with Trivaris in the SCORE study would be reached with off-label intravitreal triamcinolone acetonide preparations such as Kenalog.

#### *Dexamethasone (Ozurdex®)*

In 2009, the FDA approved a sustained-release intravitreal 0.7 mg dexamethasone (Ozurdex®) delivery sys-

tem for the treatment of macular edema secondary to RVO. Proof of its therapeutic effects on macular edema secondary to RVO was provided by the Ozurdex® GENEVA study, a 6-month randomized, controlled clinical trial, followed by an additional open phase 6-month trial [86, 87].

As a slow-release implant, its pharmacokinetics enable high concentrations of dexamethasone to be sustained in the retina and vitreous during the first 2–3 months after Ozurdex® injection, and lower concentrations are sustained up to 6 months after injection [88]. Ozurdex® has demonstrated efficacy and safety for the treatment of macular edema secondary to BRVO and CRVO [86, 87]. A prefilled, single-use applicator containing 0.7 mg of dexamethasone in a slow-release polyglycolate-acetate implant allows insertion of the drug.

The GENEVA study design included two identical, randomized, prospective, multicenter, masked, sham-controlled parallel groups. In the double-masked initial treatment phase, patients were randomly assigned (1:1:1) to receive either a 0.35 mg or a 0.7 mg dexamethasone implant, or to receive sham treatment (needleless applicator). In the second open-label phase (second injection), all eligible patients received a 0.7 mg dexamethasone implant and were followed for 6 months using the same follow-up protocol as in the initial phase. The primary endpoint was the time to achieve a 15-letter improvement (three Snellen lines) in BCVA and key secondary endpoints included BCVA over the 6-month trial period, CRT measured by OCT, and safety [86, 87].

The Ozurdex® GENEVA study demonstrated that the biodegradable implant containing 0.7 mg of dexamethasone (Ozurdex®) resulted in improved VA, revealing a peak effect after 2 months (a mean gain of 10 letters) and a progressive decline to baseline values at 6 months. VA improvement can be effectively achieved after a second injection at month 6 over a 1-year follow-up. Anatomically, improvements in macular edema were documented by OCT. Data on safety showed a low cataract rate and low rates of IOP increases. Moderately raised IOP was registered in about 15% of cases, with a peak at month 2, but pressure tended to decline over the follow-up period, especially if treated with anti-glaucomatous drops, with the majority of patients being able to discontinue the drops by 6 months after implantation. No adverse events were related to the injection. The study was also able to show that early treatment of macular edema is more beneficial than delayed treatment in restoring VA. A post hoc analysis suggested that eyes treated within 90 days of the onset of macular edema were more likely to improve than

eyes in which the treatment was instituted after this time point. This indicates a more frequent reinjection of a dexamethasone implant, dependent on the individual response of each patient over the follow-up period. Ozurdex® has received FDA and EMA approval and is licensed in all EU countries for the treatment of adult patients with macular edema following RVO [86, 87].

Recently, a similar study but with only a 2-month open-label extension showed even better efficacy in a Chinese population, with 35% of the patients improving at least 3 lines, with an average improvement of 10 letters [89]. A single intravitreal treatment with 0.7 mg Ozurdex® was shown to achieve improvements in VA as soon as 30 days after treatment, which was maintained until 90 days and in many eyes for as long as 6 months; good tolerance was also observed for a 6-month period. However, of the 797 patients who had received 0.35 or 0.7 mg Ozurdex® at the start of the study, 670 (84%) received a second injection of Ozurdex®, according to the study criteria (BCVA <84 letters or retinal thickness >250 µm, 6 months after the first injection). This proportion was slightly higher than the 82% (327/399) who met retreatment criteria from the sham injection group. Thus, at 6 months following initial injection, Ozurdex® treatment did not sustain a benefit over non-treatment. Furthermore, the decline in visual improvement observed in some eyes before the 6-month assessment point led to the conclusion that some eyes were undertreated and that evaluation for retreatment should occur earlier than 6 months. The data that were gleaned from these individuals revealed the visual prognosis to be better in BRVO- than in CRVO-afflicted eyes. A limitation of the GENEVA study was the administration of only two injections of dexamethasone at fixed 6 monthly intervals. During the intervening period, the VA deteriorated and CRT increased substantially owing to the subsidence of drug activity.

A long-term follow-up of a small series of patients who participated in the GENEVA study demonstrated no increased risk of adverse events as well as a potential benefit in VA improvement for patients with BRVO [90]. This prospective randomized trial was followed by many retrospective studies which documented the efficacy and safety of repeated treatments with Ozurdex® on a PRN basis [91–99]. The range of mean treatment intervals in these studies suggests that the optimum interval is definitely less than 6 months and that the peak effect can be seen after 2 months. No severe adverse events were observed. However, increases in IOP, which were generally transient, and cataract progression were noted. On average, improvements in VA following the first implant were

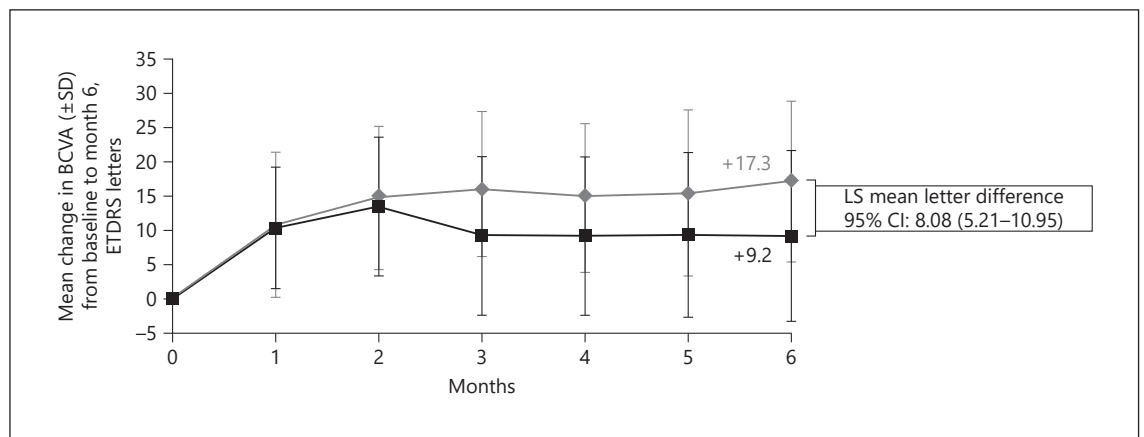
similar to those following subsequent implants. Nevertheless, considerable individual variability was observed, indicating that some eyes were undertreated.

One of the retrospective studies was a multicentered trial to find the effectiveness and safety of two or more injections of Ozurdex® in clinical practice in centers from all over Europe [100, 101]. 128 patients with macular edema secondary to RVO retreated with Ozurdex® on a PRN basis were included. The mean retreatment intervals, 5.9 and 8.7 months following first and second injections, respectively, were longer than those observed in other retrospective studies. Repeated treatment did not achieve a statistically significant change in VA. This was probably due to under-treatment related to the longer intervals between treatments. These data reflect the current practice of retreatment with Ozurdex® in Europe with the lack of clearly established guidelines for repeated treatment. The wide range of time for retreatment between individuals in different studies suggests that the main clinical goals of long-term treatment of RVO may be ensuring patient adherence to clinical visits and establishing criteria for retreatment rather than setting a specific time to treat interval [100, 101]. The multicenter LOUVRE study prospectively investigated 375 patients with RVO treated with Ozurdex®. The study showed a mean change in VA from baseline of 4.6 letters after 24 months. 39% of the patients gained ≥15 letters after 24 months [102].

Some of the retrospective studies had a large number of patients who received a large number of injections (more than 6) and showed that repeated PRN Ozurdex® injections in patients with RVO are feasible and safe [103].

Baseline characteristics have been suggested to have an important influence on the final outcome in patients treated with Ozurdex® for RVO. The importance of macular edema duration reported in the GENEVA trial has already been described above. This importance was further emphasized in a large (573 patients) prospective study where 84% of the patients received one Ozurdex® injection only [104]. An improvement in VA of +9.5, +7.3, and +5.4 approximate ETDRS letters was shown in patients with macular edema duration <90 days, from 90 to 180 days, and >180 days [104]. Improvements in BCVA through week 24 and decreases in CRT were seen in both BRVO and CRVO, as reported [105]. Patient age >55 years and initial CRT >400 µm were important risk factors associated with repeated dexamethasone intravitreal implant treatment [106].

Recently, the risk of IOP was elevated in more than 100 patients with RVO (among others) treated with Ozur-



**Fig. 18.** The COMRADE-B Study. Mean change in best-corrected visual acuity (BCVA) from baseline to month 6 (full analysis set [last observation carried forward]). Study group consists of all randomized patients who received at least one application of the study treatment and had at least one postbaseline assessment for BCVA; analysis of covariance model for least squares (LS)-means. CI, confidence interval; ETDRS, Early Treatment Diabetic Retinopathy Study; SD, standard deviation [65].

dex® [107]. Among 1,000 intravitreal injections, ocular hypertension was recorded for 28.5% of injected eyes over a mean follow-up period of 16.8 (3–55) months. IOP-lowering medication was required for 31% of eyes. Only 3 eyes with preexisting glaucoma required filtering surgery to manage postinjection IOP elevation. Furthermore, both RVO and uveitis were important risk factors for ocular hypertension after Ozurdex® injection [107].

#### Comparative Studies

The continuous release of medication by the Ozurdex® implant maintains a consistent level of drug within the eye, precluding the need for repeated injections of other medications. This is a substantial advantage of Ozurdex® over anti-VEGF agents as PRN treatment with Ozurdex® could result in only two or three injections a year, many fewer than the anti-VEGF injections required.

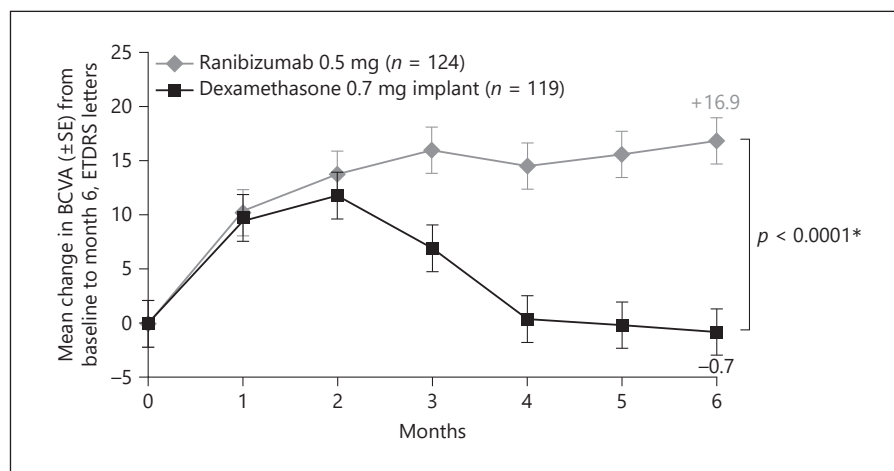
No large-scale comparative studies of anti-VEGF and corticosteroid for treatment of recurrent macular edema secondary to RVO have been reported. Some smaller-scale studies have reported comparable efficacy of both treatment regimens. One compared the results of first-line treatment of macular edema associated with BRVO in a small number of patients and reported statistically significant better mean VA and lower mean CRT in 11 eyes 1 month after one injection of Ozurdex® than in 19 eyes that received three consecutive monthly injections of bevacizumab [107]. However, no statistically significant functional or anatomic differences were observed be-

tween the groups at 3, 4, and 6 months following treatment. Although more patients in the Ozurdex® group required retreatment at 4 months, they still had an average of fewer injections than patients in the bevacizumab group (1.8 vs. 3.3). No correlation was found between functional outcomes (changes in VA) and anatomic outcomes (changes in CRT) in the two treatment groups during the 6-month follow-up period [108].

The COMRADE-B (Efficacy and Safety of Ranibizumab Intravitreal Injections versus Dexamethasone Intravitreal Implant in Patients with Branch Retinal Vein Occlusion) and the COMRADE-C (Efficacy and Safety of Ranibizumab Intravitreal Injections versus Dexamethasone Intravitreal Implant in Patients with Central Retinal Vein Occlusion) studies were two 6-month, head-to-head, phase IIIb, multicenter, randomized, double-masked studies that confirmed the efficacy and safety of intravitreal 0.5 mg ranibizumab PRN injections (according to the EMA labels, as described above [60]) in macular edema secondary to BRVO and CRVO and compared it with a single injection of the 0.7 mg dexamethasone intravitreal implant (Ozurdex®; Allergan Inc., Irvine, CA, USA) according to the EMA labels [62–64].

Both drugs were effective in reducing macular thickness and increased BCVA initially followed by a rapid and substantial improvement at month 1 and 2 with no differences between the drugs. However, the mean change in BCVA from baseline was significantly higher with ranibizumab than with dexamethasone at month 3 (+16.2

**Fig. 19.** The COMRADE-C Study. Mean change from baseline in best-corrected visual acuity (BCVA) to month 6 in patients receiving either intravitreal ranibizumab (0.5 mg) injections or a single intravitreal dexamethasone implant (0.7 mg), administered as per their European Medicines Agency label for the treatment of macular edema secondary to central retinal vein occlusion. Missing data were imputed using the last observation carried forward method. \* *p* values refer to analysis of covariance model. The error bars are  $\pm 1$  standard errors. ETDRS, Early Treatment Diabetic Retinopathy Study; SE, standard error [66].



vs. +9.3 letters in COMRADE-B and +16.0 vs. +7.0 letters in COMRADE-C) and at month 6 (+17.3 vs. +9.2 letters in COMRADE-B and +16.9 vs. -0.7 letters in COMRADE-C), with a mean of 4.71 and 4.52 injections for patients with BRVO and CRVO, respectively, showing the superiority of the PRN ranibizumab regimen driven by individualized stabilization criteria over a single injection of Ozurdex<sup>®</sup> throughout a period of 6 months [63, 64] (Fig. 18, 19). Real-life data were reported by the RANIDEX Study (Ranibizumab versus Dexamethasone Implant for Central Retinal Vein Occlusion), an observational, multicenter, retrospective study comparing the anatomic and functional outcomes of PRN intravitreal 0.5 mg ranibizumab and 0.7 mg dexamethasone implant treatments according to their EMA labels in 42 treatment-naïve patients with CRVO [65]. Both drugs were effective at 12 months, with a small but non-significant difference between the ranibizumab and the dexamethasone group (+8.4 and +6.9 letters, respectively,  $p = 0.075$ ), and edema recurrence at month 5 in the dexamethasone group, confirming previous trials data. The real-life study showed the same trend in outcomes as the clinical trial but with inferior results in terms of VA improvement, probably due to a trend to undertreatment in real life and the less restrictive criteria for selection of patients [65].

The incidence of thromboembolic events in the studies reported above was small and balanced between groups and did not suggest particular concerns in using ranibizumab in patients with RVO. The safety profile was consistent with previous phase III ranibizumab trials, with no new safety events identified in patients with BRVO and CRVO. No apparent increase or trends in systemic safety events were seen [14, 15, 43, 45, 49, 54, 56, 57,

59]. When ocular adverse events occurred, the incidence was higher with dexamethasone than with ranibizumab treatment, and a greater number of patients dropped out of the dexamethasone groups [63–65].

Another study compared Ozurdex<sup>®</sup> with ranibizumab in a retrospective non-randomized case series with 30 patients in each group and found that treatment with Ozurdex<sup>®</sup> compared with ranibizumab appeared to provide a trend towards a better VA increase after 12 months in patients with CRVO. By contrast, a trend favoring anti-VEGF treatment with ranibizumab was seen in patients with BRVO [109]. A comparison of 32 patients with RVO treated with ranibizumab and 32 treated by Ozurdex<sup>®</sup> did not find any difference in BCVA or reduction in CRT. There was a statistically significant increase in IOP in patients treated with Ozurdex<sup>®</sup> [110].

The OMAR study compared the risks and benefits of adding either Ozurdex<sup>®</sup> or preservative-free triamcinolone acetonide to bevacizumab monotherapy in refractory macular edema due to RVO in a multicenter comparative interventional, retrospective study that included 74 patients who were initially treated with intravitreal bevacizumab and later received triamcinolone ( $n = 35$ ) or triamcinolone acetonide ( $n = 39$ ) for the treatment of recalcitrant macular edema due to RVO [111]. Although the mean CRT improved significantly for all groups ( $p < 0.0001$ ), logMAR BCVA did not change significantly after steroid introduction ( $p = 0.06$ ). This can most likely be attributed to existing photoreceptor damage in eyes with long-standing refractory macular edema. The frequency of bevacizumab injections decreased significantly from  $0.66 \pm 0.18$  to  $0.26 \pm 0.08$  injections per month after the initiation of steroid treatment ( $p < 0.0001$ ). This effect



was greater in the Ozurdex<sup>®</sup> groups ( $p < 0.0001$ ). The monthly costs decreased with triamcinolone acetonide but increased with Ozurdex<sup>®</sup> [111].

Ozurdex<sup>®</sup> was compared with bevacizumab for the treatment of CRVO in a prospective study with 30 eyes in each group [112]. No significant difference in BCVA was found between the two groups during 6 months ( $p > 0.05$ ). The bevacizumab group had a significantly lower CRT at 1 month ( $p = 0.006$ ) and no difference for the rest of the 6 months ( $p > 0.05$ ). There was a significantly higher IOP for the dexamethasone implant group (compared with bevacizumab) at 3–6 months ( $p < 0.05$ ). It was concluded that both drugs demonstrated comparable efficacy in BCVA improvement and CRT reduction [112].

#### *Combination Therapy Studies*

There are no controlled studies investigating the effect of combination therapy. An open-label, interventional case series of patients with RVO who received treatment cycles which included an anti-VEGF injection followed by an Ozurdex<sup>®</sup> implant 2 weeks later has been reported [113]. The combination therapy was found to lead to an increase in the mean reinjection interval over the regular interval in anti-VEGF monotherapy ( $135.5 \pm 36.4$  days over 6 treatment cycles for both CRVO and BRVO, with a mean peak change in BCVA of +13.8 letters and 47.6% of the eyes gaining three or more lines of BCVA). In eyes with macular edema due to RVO, treatment with an anti-VEGF agent plus Ozurdex<sup>®</sup> implant provided a predictable duration of effect as well as statistically significant anatomic and functional improvements [113].

Another study in which a group of patients treated with Ozurdex<sup>®</sup> only was compared with a group in which bevacizumab was added after 1 month if there was still macular edema found that the combination was synergistic [114]. A comparison of the efficacy and safety of a loading phase with three intravitreal bevacizumab injections followed by a dexamethasone implant and dexamethasone implant monotherapy in 64 eyes with macular edema due to RVO found no difference between the two treatment strategies in CRVO. However, dexamethasone implant monotherapy was associated with better functional outcomes in BRVO [115].

A short-term (3-month) study with a small number of patients that evaluated the safety and efficacy of combining intravitreal dexamethasone implantation (Ozurdex<sup>®</sup>) with pars plana vitrectomy (PPV) found good functional and anatomic results with no safety concerns [116]. While 129 patients treated with multiple Ozurdex<sup>®</sup> injections and then required conversion to ranibizumab who were

retrospectively evaluated for 20 months showed a statistically significant improvement in BCVA of 16 letters. In conclusion, the use of ranibizumab was safe in eyes previously treated with Ozurdex<sup>®</sup> [117].

#### **Recommendation**

Based on the data that exist thus far, it is evident that corticosteroids are important in our armamentarium of drugs for treating patients with RVO, but largely on a second-choice level. Hence, switching to a steroid in non-responders who have already been treated with anti-VEGF (after 3–6 injections, depending on the specific response of each patient) is reasonable.

Steroids may be considered as a first-line therapy for patients who have a recent history of a major cardiovascular event as these patients had to be excluded from all major anti-VEGF trials and thus could not receive anti-VEGF as first-line therapy.

Another group of patients in whom corticosteroids may be considered as first-line therapy are those who are unwilling to come for monthly injections (and/or monitoring) in the first 6 months of therapy. However, these patients' IOP still needs to be monitored every 2 to 8 weeks following injection as in every patient who underwent Ozurdex<sup>®</sup> implantation. The first cycles after implantation need close monitoring after every 2 weeks to see the patients IOP response.

A complete examination including VA and OCT imaging should be performed 3 months after an Ozurdex<sup>®</sup> injection and repeated if macular edema is still found present on OCT or VA has decreased. Retreatment with Ozurdex<sup>®</sup> will generally be performed after 3–4 months, with a mean of approximately 2–3 injections per year. Patients with pseudophakic eyes are preferable for the use of steroids, otherwise patients have to be informed about the high risk for cataract formation leading to cataract surgery.

From the body of data that has been collected to date, it is evident that the effects of Ozurdex<sup>®</sup> can be sustained for about 4 months. Retreatment therapy with a PRN regimen would necessitate reinjection intervals of substantially less than 6 months for the vast majority of eyes.

#### **Surgical Intervention**

##### ***Vitrectomy*** **Rationale**

Vitreous surgery is considered to re-perfuse the thrombosed vein, achieve a choroidal drainage of the retinal cir-

culation, or increase the exchange of fluid between the retina and the vitreous. Vitrectomy has different physiological and clinical consequences in an eye with RVO: there is evidence that vitrectomy increases the transport of oxygen to ischemic areas and increases the clearance of VEGF and cytokines in the vitreous cavity. Moreover, the increase in oxygenation reduces VEGF, with a temporary reduction of macular edema. On the other hand, the increase in oxygen stimulates cataract formation and vitrectomy increases the flow of VEGF to the anterior chamber, increasing the risk of iris neovascularization [118].

#### *Central Retinal Vein Occlusion*

PPV techniques are used to address complications of CRVO and, in investigational studies, to attempt to alter the natural course of the disease. Eyes with non-clearing vitreous hemorrhage from secondary retinal neovascularization may require surgical evacuation. At the time of vitrectomy, clearing of the hemorrhage can be combined with removal of epiretinal membranes and if present fibrovascular proliferations and the placement of complete PRP [119]. Although this technique may prevent or aid regression of anterior segment neovascularization, visual outcomes may be limited due to the extent of underlying retinal non-perfusion [120].

#### **Evidence**

In eyes with extensive anterior segment neovascularization and neovascular glaucoma, vitrectomy and endolaser PRP may be combined with pars plana placement of a glaucoma drainage device to avoid anterior chamber hemorrhage at the time of tube placement. Some authors suggest peeling the internal limiting membrane (ILM) also to improve oxygenation of the fovea and the anatomic and functional outcomes of vitrectomy [121]. Other authors showed improvement in retinal edema with a decrease in foveal thickness but no statistically significant change in vision [122].

The presence of vitreoretinal macular traction can generate macular distortion with fluid (with a similar appearance to macular edema per se), and a release of this anterior-posterior vector force is recommended to recover the prior anatomic situation. However, surgery is controversial when tangential traction is present, especially with regard to the presence of vascular permeability alteration.

#### **Recommendation**

The use of vitrectomy with or without membrane peeling in the management of macular edema secondary to CRVO requires further randomized trials to establish its

efficacy compared with the actual gold standard management, which is the intravitreal injection of anti-VEGF drugs. This is particularly important because vitrectomy increases the intravitreal clearance of these agents, which may reduce the duration of the effect and result in decreased efficacy of further intravitreal pharmacotherapy [123].

#### **Radial Optic Neurotomy**

##### **Rationale**

Combining PPV with transvitreal incision of the nasal scleral ring has been proposed to release pressure on the central retinal vein at the level of the scleral outlet [124]. The procedure addresses the “compartment syndrome” that may exist in these eyes, where the central retinal artery, central retinal vein and optic nerve traverse through a 1.5-mm diameter area. Vascular factors as well as rigidity of the scleral ring may also decrease the venous lumen and incite a thrombotic event. Previous attempts at external decompression of the orbital portion of the optic nerve by optic nerve sheath fenestration and sectioning of the posterior scleral ring have not been validated as effective treatments in CRVO [125, 126].

Radial optic neurotomy (RON) is performed as PPV followed by use of a 25-gauge microvitoretinal blade to incise the lamina cribrosa and adjacent retina. Care is taken to avoid major retinal vessels, and a radial incision orientation is used to avoid transecting nerve fibers. Intraoperative hemorrhage is typically controlled by transient elevation of IOP.

##### **Evidence**

PPV was combined with RON involving transvitreal incision of the nasal scleral ring to release pressure on the central retinal vein at the level of the scleral outlet [124].

A prospective interventional trial reported (evidence level II) successful RON surgery in 14 eyes [127]. Overall, 57% gained one line of distance VA, and visual recovery was statistically significantly related to a reduction in macular edema. Six eyes (43%) developed a postoperative chorioretinal anastomosis (CRA) at the RON site with a trend towards better final VA than those without anastomosis formation (20/60 vs. 20/110). The CRA seen at RON sites may allow for more active drainage of macular edema and hemorrhage compared with laser-induced CRA.

When evaluating the effectiveness of RON for CRVO in patients <50 years of age versus those >50 in a group of 43 patients (evidence level II) [128], better functional results were observed in the younger patients (50 vs. 30%

gained 15 letters), although functional improvement remained limited in those with low baseline VA. RON seems to be a potential treatment for selected patients with hemicentral RVO, probably because of the more rapid appearance of chorioretinal collateral vessels that promote faster resolution of macular edema. Gains of 2 or more Snellen lines of vision were reported in 69.2% of 13 patients, and in 4 patients (30.8%) VA improved by 4 or more Snellen lines (evidence level II) [129].

A publication in 2006 reported on 117 patients with CRVO and severe VA loss ( $\leq 20/200$ ) treated with PPV and RON (evidence level II) [130]. Anatomic improvement of CRVO was found in 95% of the patients. Disc edema improved by 1 week, although most improvements were observed at 2 and 3 months. VA improved in 71% of the patients, with an average of 2.5 lines of vision gained. Subgroup analyses suggested that older age, female sex, duration of CRVO, presence of afferent pupillary defect, absence of perfusion by angiography, and development of anterior segment neovascularization were associated with poorer visual outcomes. No study has replicated the reported 71% improvement, and some studies have reported that visual improvement following RON is comparable to natural history [131].

The only prospective, placebo-controlled, randomized, multicenter study was the ROVO (Radial Optic Neurotomy for Central Vein Occlusion) Study (evidence level I). Ninety patients with CRVO were treated in three groups with RON, a single intravitreal injection of 4 mg triamcinolone acetonide or a placebo treatment. The main outcome measures were a change in VA and the proportion of eyes with a noteworthy improvement (defined as  $>3$  lines log MAR scale) of VA from baseline to month 12. Seven patients were excluded due to insufficient data. 47% percent ( $n = 18$ ) of the patients treated with RON showed an increase in VA compared with 10% ( $n = 2$ ) of placebo-treated patients and 20% ( $n = 5$ ) of patients treated with triamcinolone acetonide. Significantly more patients showed an improvement in VA following RON than in the placebo group ( $p = 0.009$ ) and in the triamcinolone acetonide group ( $p = 0.034$ ). Significantly more patients showed a deterioration (defined as  $>3$  lines logMAR scale) in VA in the placebo (35%,  $n = 7$ ) than in the RON group (8%,  $n = 3$ ) ( $p = 0.007$ ). The study showed that following treatment with RON, patients with CRVO display a significantly better long-term VA than untreated patients and patients treated with a single dose of triamcinolone acetonide [132].

By contrast, other studies have not demonstrated improvement in VA [133] or in central retinal hemodynam-

ics [134, 135], questioning the role for RON in CRVO treatment. Importantly, RON has been associated with important risks, including postoperative visual field defects, in relation with neurotomy, damage of central retinal vessels, choroidal neovascularization, subretinal hemorrhage, and retinal detachment [131, 136].

### Recommendation

Evidence for the efficacy of RON in the management of CRVO is limited and currently does not clearly demonstrate a benefit. The use of RON for CRVO has largely been abandoned due to the availability of effective intravitreal pharmacologic agents.

#### *Branch Retinal Vein Occlusion*

##### Vitrectomy

### Rationale

There is evidence that vitreomacular attachment itself may contribute to the development of macular edema in BRVO [137]. The few published studies that report outcomes of PPV for complications of BRVO consist only of case reports and small case series, the limitations of which include small sample sizes and a lack of comparison groups [138].

### Evidence

Despite the absence of large clinical trials, recently PPV has been demonstrated to improve perifoveal microcirculation and the visual prognosis in patients with BRVO and macular edema [139].

Some authors have proposed a peeling of the ILM to improve oxygenation of the fovea and anatomic and functional outcomes of vitrectomy. A short series of cases found good outcomes with this technique [140]. On the other hand, no difference was found in a non-randomized, comparative study between PPV with and without ILM peeling for BRVO, and the conclusion was that there is no additional benefit in removing the ILM for BRVO-associated macular edema [141].

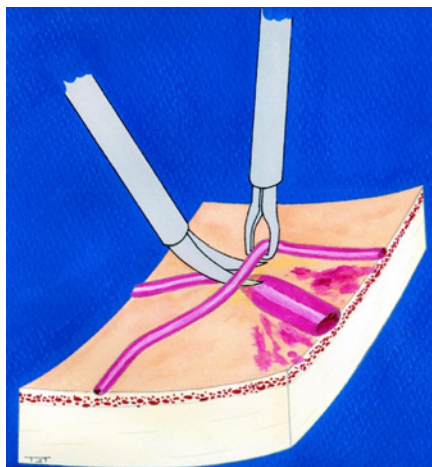
### Recommendation

Lack of data and the availability of intravitreal pharmacotherapy do not allow any recommendation for PPV in eyes with macular edema due to BRVO.

##### Sheathotomy

### Rationale

The first report of sheathotomy for BRVO [142] was published a few years after histologic changes in BRVO were described in 1988 [143]. Only 1 case with a statisti-



**Fig. 20.** Bimanual dissection of the common adventitial sheath at the arteriovenous crossing, to relieve the compression of the vein and re-establish the blood flow. Image is presented courtesy of Jose Garcia-Arumi.

cally significant visual improvement after surgery was presented. Despite the technique's success, this treatment was abandoned for nearly 10 years. In 1998, venous narrowing at the crossing site was again described as the main cause for BRVO, and removal of the compressive factor by sectioning the adventitial sheath (sheathotomy) suggested an effective treatment for BRVO [144]. A case series of 15 patients with BRVO treated with sheathotomy was reported 1 year later [145].

This surgical technique consists of a PPV with posterior hyaloid dissection. The arteriovenous crossing must be dissected with special forceps and scissors. At this point, the experience of the surgeon plays an important role because small tractions may break the vein (Fig. 20). A revision of the peripheral retina should be performed to avoid iatrogenic breaks and no tamponade other than serum is needed.

Potential benefits of sheathotomy include the mechanic decompression of the venule and thrombus release that can sometimes be achieved during the surgery. Successful decompressive surgery is usually followed by a disappearance of collateral vessels at the BRVO blockage site, which is a clinical marker for intravascular reperfusion, and resolution of hemorrhages and macular edema (Fig. 21, 22).

### Evidence

Forty-three patients with macular edema secondary to BRVO were treated with arteriovenous decompression, while 25 patients with similar BRVO who refused this

surgical intervention served as a control group. The functional results in patients with arteriovenous decompression were highly statistically significantly better than in the control group (evidence level II) [146]. Arteriovenous sheathotomy using a bimanual technique, followed by fluid-air exchange and injection of 25 mg of recombinant tissue plasminogen activator over the area of the occluded vein was reported in 40 patients. Thrombus release was observed in 11 patients (27.5%) and was correlated with early surgery ( $p < 0.001$ ) and better final visual recovery ( $p < 0.06$ ). OCT showed CRT decrease by more than 40% in 31 patients (77.5%) compared with the preoperative status and correlated to postoperative VA ( $p < 0.001$ ). The mean VA increased from 20/100 to 20/40, with 70% of the patients gaining three or more lines of VA (Pearson 0.378,  $p = 0.016$ ) (evidence level II) [147].

A randomized, prospective trial compared vitrectomy plus arteriovenous sheathotomy with intravitreal triamcinolone acetonide with 20 patients in each group. At 6 months, the functional and anatomic outcomes were similar, although triamcinolone acetonide achieved those results more quickly. At 1 month, the triamcinolone acetonide group had a higher mean IOP than the arteriovenous sheathotomy group ( $p = 0.029$ ). Cataract progression was noted in both groups (evidence level I) [148].

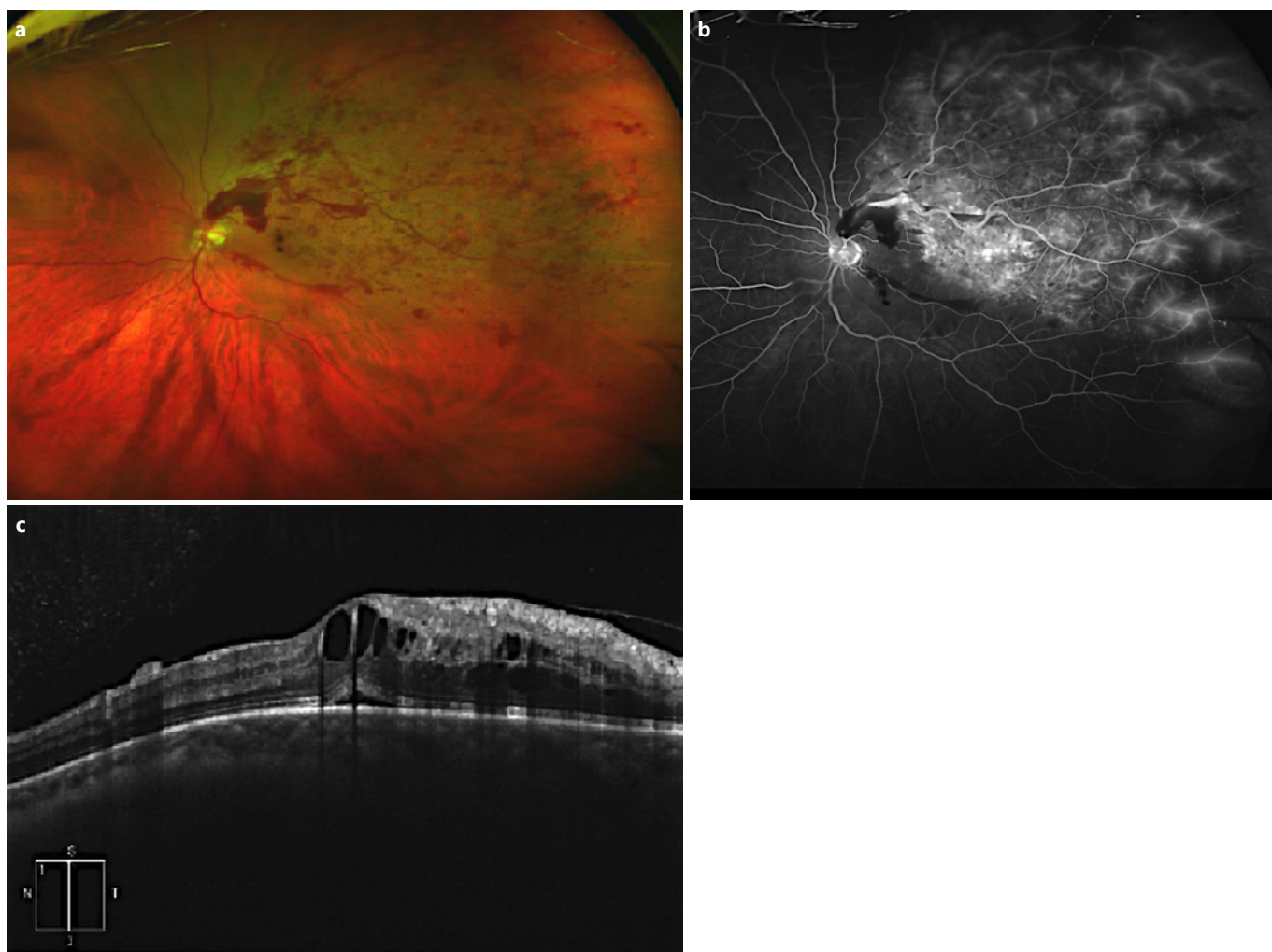
A prospective, randomized, interventional case series, in which 36 eyes were enrolled, compared vitrectomy with vitrectomy plus arteriovenous sheathotomy. VA and macular edema improved in both groups over the 12-month duration of the study, but there was no difference in the final outcomes between the two groups. However, there was no control group to compare the natural disease course. There was a trend towards greater visual improvement with arteriovenous sheathotomy in eyes with a BRVO duration of less than 4 weeks at study entry ( $p = 0.064$ ) (evidence level II) [149].

### Recommendation

Alternative therapies such as vitrectomy, ILM peeling, and arteriovenous sheathotomy may play a role in selected cases of BRVO, but the overall evidence for these approaches is limited. Due to the risk of intraoperative complications and the availability of less invasive alternatives, vitrectomy with or without sheathotomy has restricted clinical use as a first-line treatment. Current evidence on comparative therapy across and within drug classes is limited. Robust evidence on combination therapy is also lacking.

New imaging technology, including OCT angiography and ultra-widefield angiography, may in the future play a





**Fig. 21. a** Wide-field retinography showing hemorrhages and edema in the field of the thrombosed vein (superotemporal) of the left eye of a 56-year-old man, with 1 week of evolution. Image is presented courtesy of Jose Garcia-Arumi. **b** Wide-field fluorescein angiography showing leakage of the capillary network in the area of the obstructed superotemporal vein, the arteriovenous crossing,

and the peripheral ischemia. Image is presented courtesy of Jose Garcia-Arumi. **c** Macular OCT of the same patient with subfoveal fluid and macular edema with cystic spaces. Best-corrected visual acuity was at this time 20/60. Image is presented courtesy of Jose Garcia-Arumi.

role in the approach to therapeutics and prognosis. Additional research on these treatment modalities is needed to better explain their role in disease management.

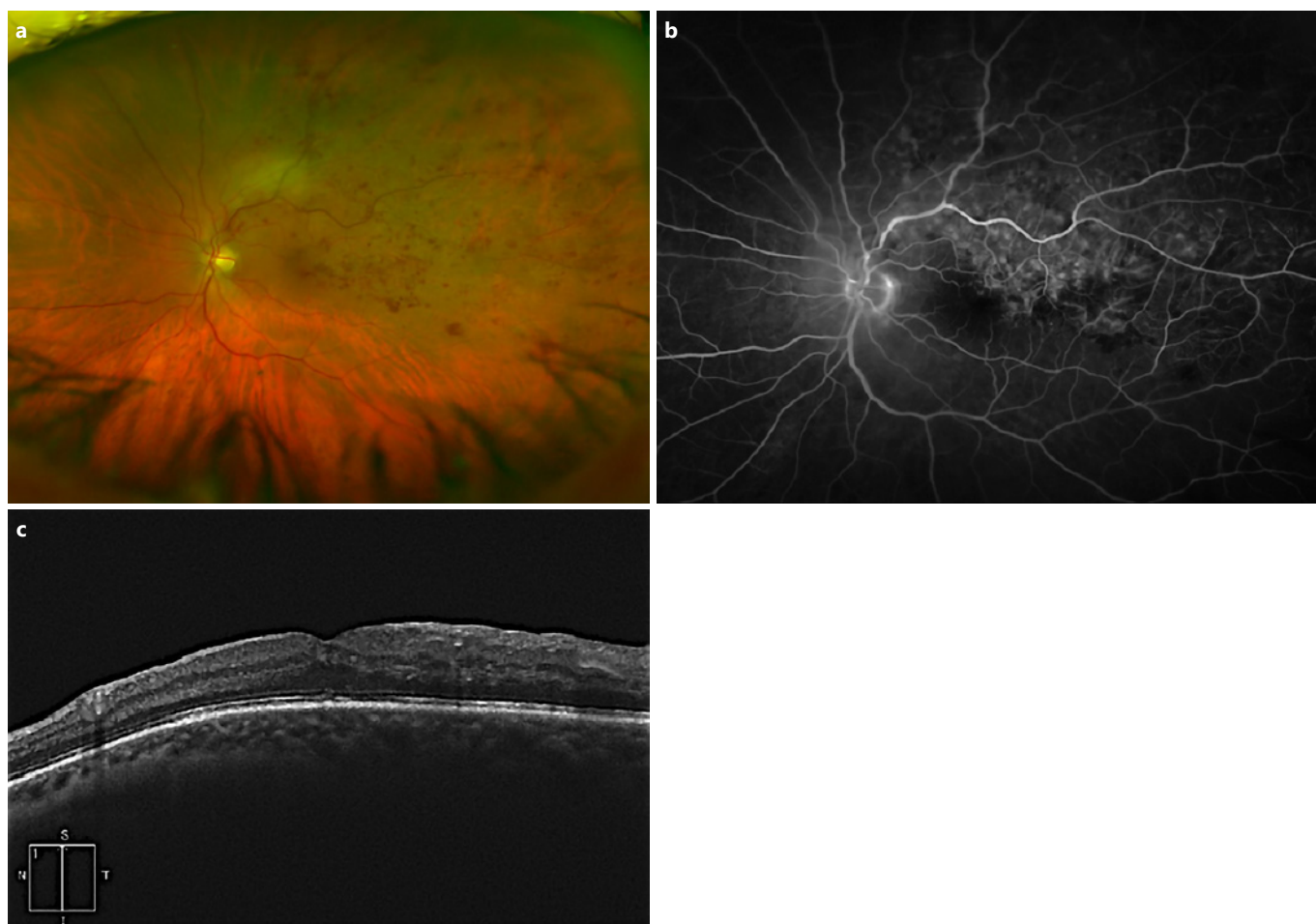
## Risk Factors and Systemic Evaluation

### Rationale

Established cardiovascular risk factors are the most common risk factors for both CRVO and BRVO. Hypertension is the predominant risk factor for this condition in older patients ( $\geq 50$  years). Uncontrolled hypertension

may be newly diagnosed on presentation with either RVO. Similarly, inadequately controlled hypertension is associated with recurrence of RVO in the same eye or fellow eye involvement. Hyperlipidemia is a common risk factor in younger patients ( $< 50$  years), especially in BRVO and may also be present in up to 50% of older patients. Secondary causes of hypercholesterolemia including hypothyroidism should also be considered.

Diabetes is associated with RVO, but this may be because both diabetes and RVO are associated with cardiovascular risk factors. Similarly, for the same reason, there is conflicting evidence of a higher incidence of cardiovas-



**Fig. 22.** **a** Wide-field retinography after 3 months of vitrectomy and sheathotomy with an important decrease in retinal hemorrhages and edema. Image is presented courtesy of Jose Garcia-Arumi. **b** Wide-field angiography shows disappearance of peripheral ischemia and macular edema. Image is presented courtesy of Jose

Garcia-Arumi. **c** Macular OCT 3 months after surgery with resorption of macular edema and subfoveal fluid. Best-corrected visual acuity improved to 20/25. Image is presented courtesy of Jose Garcia-Arumi.

cular and cerebrovascular morbidity and mortality in patients with RVO compared with control groups.

Primary open-angle glaucoma is also a risk factor for CRVO.

Blood coagulation and hyperviscosity disorders including myeloproliferative disorders, Waldenström's macroglobulinemia, factor V Leiden thrombophilia, disturbances of the protein S and C pathways, anti-thrombin 3 deficiency, and the use of oral contraceptives are known causes of RVO in younger patients. Systemic inflammatory disorders that cause retinal vasculitis including Behçet's disease, polyarteritis nodosa, sarcoidosis, granulomatosis with polyangiitis (Wegener's), and Goodpasture's syndrome may also be responsible for RVO. Anatomic risk factors such as short axial length may con-

tribute to the development of BRVO. Rarely, retrobulbar compressive pathology such as thyroid eye disease, orbital tumor, or retrobulbar hemorrhage may be a cause.

### Evidence

The Eye Disease Case-Control Study compared 258 patients with CRVO with an age-matched control group and showed that systemic hypertension, diabetes, and glaucoma are associated with CRVO. These associations were higher with ischemic CRVO [150].

The Danish National Patient Registry Study showed that hypertension was twice as common in CRVO compared with a control group [151]. A similar finding was observed in the GENEVA Study, where hypertension was found in 68% of affected eyes compared with 55% in a

control group, OR of 2.03 (1.48–2.78) [87]. However, prevalence of hypertension is as high as 66.7% in people aged  $\geq 60$  years, and the prevalence of diabetes in patients with RVO is no higher than in the same age group in the general population. However, both blood pressure and blood sugar should be tested in people with RVO to detect undiagnosed hypertension and diabetes.

The evidence of increased prevalence of stroke in patients with RVO is conflicting. A hospital-based study [152] and a population-based study [153] suggest no evidence, while another study reported a similar incidence of stroke both before and after the diagnosis of CRVO [151]. Contrary to these results, a pooled cohort of two population-based studies found that men with RVO at all ages have a 2.3 times higher non-significant risk of cerebrovascular mortality [154]. Pooled data from both the Atherosclerosis Risk in Communities Study and the Cardiovascular Health Study also showed that carotid artery plaques are more common in patients with RVO [155]. Similarly, the evidence on the risk of higher overall increased mortality in patients with CRVO or BRVO is also equivocal [156, 157]. Despite the conflicting evidence, systemic evaluation and treatment of cardiovascular risk factors by the patient's physician are advocated in young men with RVO and in older patients with no previous history of these risk factors. Among others, known risk factors are hyperviscosity, inflammation, and coagulation dysfunction.

### Recommendations

It is recommended that the minimum investigation of a patient newly diagnosed with RVO in an eye clinic should include a detailed medical history, measurement of blood pressure and sugar, and basic laboratory tests of the full blood count, erythrocyte sedimentation rate, and c-reactive protein measurement. To avoid nightly non-dipping or over-dipping, 24-h blood pressure measurements as regular follow-up via the general practitioners are recommended. The results will allow urgent treat-

ment of any newly diagnosed or uncontrolled cardiovascular risk factors and help to rule out any rarer conditions such as blood dyscrasias, myeloma, or an inflammatory cause. Further tests as needed are best performed by the general physician based on the history and results of initial investigations. Bilateral presentation or any sign of a vascular disturbance in the other eye suggests an underlying systemic condition. Younger patients with RVO in whom no common risk factors have been identified may require a comprehensive systemic evaluation. They may additionally be screened for thrombophilia including antiphospholipid antibody syndrome, although this association is weak. Women already receiving estrogen-containing hormone replacement therapy may continue with it after an informed decision is made, but such therapy should not be commenced in women with RVO.

### Acknowledgement

The authors would like to express their sincere gratitude to Elise Langdon-Neuner for editing the manuscript for language and Dr. Martina Neschi for her contribution in preparing, editing and formatting the manuscript material.

### Disclosure Statement

S. Sivaprasad has received research grants, travel grants, speaker fees and attended advisory board meetings of Novartis, Bayer, Allergan. S. Sivaprasad has received research grants, attended advisory board meetings of Roche, Optos, Boehringer. S. Sivaprasad attended advisory board meetings of Heidelberg.

Anat Loewenstein: consultant for Allergan, Bayer, Novartis, Notal Vision, Syneos Health, Beyeonics Surgical; grant/research support from Multicentre trial, Sensor, Novartis, Allergan, Bayer; speaker's bureau participant with none; honoraria/honorarium ad hoc from the above companies; major stock shareholder in none; advisory board for Allergan, Bayer, Novartis, Notal Vision, Beyeonics; other financial or material support – none.

All other authors have no conflicts of interest to disclose relevant to this work.

### References

- 1 Ho M, Liu DT, Lam DS, Jonas JB. Retinal vein occlusions, from basics to the latest treatment. *Retina*. 2016 Mar;36(3):432–48.
- 2 Ehlers JP, Fekrat S. Retinal vein occlusion: beyond the acute event. *Surv Ophthalmol*. 2011 Jul-Aug;56(4):281–99.
- 3 Khayat M, Williams M, Lois N. Ischemic retinal vein occlusion: characterizing the more severe spectrum of retinal vein occlusion. *Surv Ophthalmol*. 2018 Nov - Dec;63(6):816–50.
- 4 Hayreh SS, Fraterriro L, Jonas J. Central retinal vein occlusion associated with cilioretinal artery occlusion. *Retina*. 2008 Apr;28(4):581–94.
- 5 Phasukkijwatana N, Rahimi M, Iafe N, Sarraf D. Central retinal vein occlusion and paracentral acute middle maculopathy diagnosed with en face optical coherence tomography. *Ophthalmic Surg Lasers Imaging Retina*. 2016 Sep;47(9):862–4.
- 6 Prisco D, Marcucci R, Bertini L, Gori AM. Cardiovascular and thrombophilic risk factors for central retinal vein occlusion. *Eur J Intern Med*. 2002 May;13(3):163–9.
- 7 Garcia-Horton A, Al-Ani F, Lazo-Langner A. Retinal vein thrombosis: the Internist's role in the etiologic and therapeutic management. *Thromb Res*. 2016 Dec;148:118–24.



- 8 Rajagopal R, Apte RS. Seeing through thick and through thin: retinal manifestations of thrombophilic and hyperviscosity syndromes. *Surv Ophthalmol*. 2016 Mar-Apr; 61(2):236–47.
- 9 Fong AC, Schatz H. Central retinal vein occlusion in young adults. *Surv Ophthalmol*. 1993 May-Jun;37(6):393–417.
- 10 Chan CK, Ip MS, Vanveldhuisen PC, Oden NL, Scott IU, Tolentino MJ, et al.; SCORE Study Investigator Group. SCORE Study report #11: incidences of neovascular events in eyes with retinal vein occlusion. *Ophthalmology*. 2011 Jul;118(7):1364–72.
- 11 A randomized clinical trial of early panretinal photocoagulation for ischemic central vein occlusion. The Central Vein Occlusion Study Group N report. *Ophthalmology*. 1995 Oct; 102(10):1434–44.
- 12 Girmens JF, Glacet-Bernard A, Kodjikian L, Nghiem-Buffet S, Massé H, Fourmaux E, et al. [Management of macular edema secondary to retinal vein occlusion]. *J Fr Ophtalmol*. 2015 Mar;38(3):253–63.
- 13 Arsene S, Vierron E, Le Lez ML, Herault B, Gruel Y, Pisella PJ, et al. Conversion from nonischemic to ischemic retinal vein occlusion: prediction by venous velocity on color Doppler imaging. *Eur J Ophthalmol*. 2009 Nov-Dec;19(6):1009–16.
- 14 Wang K, Ghasemi Falavarjani K, Nittala MG, Sagong M, Wyckoff CC, van Hemert J, et al. Ultra-wide-field fluorescein angiography-guided normalization of ischemic index calculation in eyes with retinal vein occlusion. *Invest Ophthalmol Vis Sci*. 2018 Jul;59(8): 3278–85.
- 15 Tan CS, Chew MC, van Hemert J, Singer MA, Bell D, Sadda SR. Measuring the precise area of peripheral retinal non-perfusion using ultra-widefield imaging and its correlation with the ischaemic index. *Br J Ophthalmol*. 2016 Feb;100(2):235–9.
- 16 Larsen M, Waldstein SM, Boscia F, Gerding H, Monés J, Tadayoni R, et al.; CRYSTAL Study Group. Individualized ranibizumab regimen driven by stabilization criteria for central retinal vein occlusion: twelve-month results of the crystal study. *Ophthalmology*. 2016 May;123(5):1101–11.
- 17 Tadayoni R, Waldstein SM, Boscia F, Gerding H, Gekkieva M, Barnes E, et al.; BRIGHTER Study Group. Sustained benefits of ranibizumab with or without laser in branch retinal vein occlusion: 24-month results of the brighter study. *Ophthalmology*. 2017 Dec; 124(12):1778–87.
- 18 Schmidt-Erfurth U, Chong V, Loewenstein A, Larsen M, Souied E, Schlingemann R, et al.; European Society of Retina Specialists. Guidelines for the management of neovascular age-related macular degeneration by the European Society of Retina Specialists (EURETINA). *Br J Ophthalmol*. 2014 Sep;98(9):1144–67.
- 19 Schmidt-Erfurth U, Garcia-Arumi J, Bandello F, Berg K, Chakravarthy U, Gerendas BS, et al. Guidelines for the management of diabetic macular edema by the European society of retina specialists (EURETINA). *Ophthalmologica*. 2017;237(4):185–222.
- 20 Vogl WD, Waldstein SM, Gerendas BS, Schmidt-Erfurth U, Langs G. Predicting macular edema recurrence from spatio-temporal signatures in optical coherence tomography images. *IEEE Trans Med Imaging*. 2017 Sep; 36(9):1773–83.
- 21 Vogl WD, Waldstein SM, Gerendas BS, Schlegl T, Langs G, Schmidt-Erfurth U. Analyzing and predicting visual acuity outcomes of anti-vegf therapy by a longitudinal mixed effects model of imaging and clinical data. *Invest Ophthalmol Vis Sci*. 2017 Aug;58(10): 4173–81.
- 22 Waldstein SM, Montuoro A, Podkowinski D, Philip AM, Gerendas BS, Bogunovic H, et al. Evaluating the impact of vitreomacular adhesion on anti-VEGF therapy for retinal vein occlusion using machine learning. *Sci Rep*. 2017 Jun;7(1):2928.
- 23 Podkowinski D, Philip AM, Vogl WD, Gamber J, Bogunovic H, Gerendas BS, et al. Neuroretinal atrophy following resolution of macular oedema in retinal vein occlusion. *Br J Ophthalmol*. 2019 Jan;103(1):36–42.
- 24 Chatziralli IP, Sergentanis TN, Sivaprasad S. Hyperreflective foci as an independent visual outcome predictor in macular edema due to retinal vascular diseases treated with intravitreal dexamethasone or ranibizumab. *Retina*. 2016 Dec;36(12):2319–28.
- 25 Mo B, Zhou HY, Jiao X, Zhang F. Evaluation of hyperreflective foci as a prognostic factor of visual outcome in retinal vein occlusion. *Int J Ophthalmol*. 2017 Apr;10(4):605–12.
- 26 Kang JW, Lee H, Chung H, Kim HC. Correlation between optical coherence tomographic hyperreflective foci and visual outcomes after intravitreal bevacizumab for macular edema in branch retinal vein occlusion. *Graefes Arch Clin Exp Ophthalmol*. 2014 Sep;252(9):1413–21.
- 27 Ogino K, Murakami T, Tsujikawa A, Miyamoto K, Sakamoto A, Ota M, et al. Characteristics of optical coherence tomographic hyperreflective foci in retinal vein occlusion. *Retina*. 2012 Jan;32(1):77–85.
- 28 Mimouni M, Segev O, Dori D, Geffen N, Flores V, Segal O. Disorganization of the retinal inner layers as a predictor of visual acuity in eyes with macular edema secondary to vein occlusion. *Am J Ophthalmol*. 2017 Oct;182: 160–7.
- 29 Rahimy E, Sarraf D, Dollin ML, Pitcher JD, Ho AC. Paracentral acute middle maculopathy in nonischemic central retinal vein occlusion. *Am J Ophthalmol*. 2014 Aug;158(2): 372–380.e1.
- 30 Ko J, Kwon OW, Byeon SH. Optical coherence tomography predicts visual outcome in acute central retinal vein occlusion. *Retina*. 2014 Jun;34(6):1132–41.
- 31 Wang Q, Chan SY, Yan Y, Yang J, Zhou W, Jonas JB, et al. Optical coherence tomography angiography in retinal vein occlusions. *Graefes Arch Clin Exp Ophthalmol*. 2018;256(9): 1615–22.
- 32 Winegarner A, Wakabayashi T, Hara-Ueno C, Sato T, Busch C, Fukushima Y, et al. Retinal microvasculature and visual acuity after intravitreal aflibercept in eyes with central retinal vein occlusion: an optical coherence tomography angiography study. *Retina*. 2018 Oct;38(10):2067–72.
- 33 Hasegawa T, Murakawa S, Maruko I, Kogure-Katakura A, Iida T. Correlation between reduction in macular vessel density and frequency of intravitreal ranibizumab for macular oedema in eyes with branch retinal vein occlusion. *Br J Ophthalmol*. 2019 Jan;103(1): 72–7.
- 34 Hasegawa T, Takahashi Y, Maruko I, Kogure A, Iida T. Macular vessel reduction as predictor for recurrence of macular oedema requiring repeat intravitreal ranibizumab injection in eyes with branch retinal vein occlusion. *Br J Ophthalmol*. 2018 Dec;bjophthalmol-2018-312769.
- 35 Ghahshat R, Muraoka Y, Ooto S, Iida Y, Miwa Y, Suzuma K, et al. Evaluation of macular ischemia in eyes with central retinal vein occlusion: an optical coherence tomography angiography study. *Retina*. 2018 Aug;38(8):1571–80.
- 36 Wakabayashi T, Sato T, Hara-Ueno C, Fukushima Y, Sayanagi K, Shiraki N, et al. Retinal microvasculature and visual acuity in eyes with branch retinal vein occlusion: imaging analysis by optical coherence tomography angiography. *Invest Ophthalmol Vis Sci*. 2017 Apr;58(4):2087–94.
- 37 Kang JW, Yoo R, Jo YH, Kim HC. Correlation of microvascular structures on optical coherence tomography angiography with visual acuity in retinal vein occlusion. *Retina*. 2017 Sep;37(9):1700–9.
- 38 Casselholmde Salles M, Kvanta A, Amrén U, Epstein D. Optical coherence tomography angiography in central retinal vein occlusion: correlation between the foveal avascular zone and visual acuity. *Invest Ophthalmol Vis Sci*. 2016 Jul;57(9):OCT242–6.
- 39 Suzuki N, Hirano Y, Tomiyasu T, Kurobe R, Yasuda Y, Esaki Y, et al. Collateral vessels on optical coherence tomography angiography in eyes with branch retinal vein occlusion. *Br J Ophthalmol*. 2018 Nov;bjophthalmol-2018-313322.
- 40 The Central Vein Occlusion Study Group. Natural history and clinical management of central retinal vein occlusion. *Arch Ophthalmol*. 1997 Apr;115(4):486–91.
- 41 Stefánsson E. The therapeutic effects of retinal laser treatment and vitrectomy. A theory based on oxygen and vascular physiology. *Acta Ophthalmol Scand*. 2001 Oct;79(5):435–40.
- 42 The Branch Vein Occlusion Study Group. Argon laser photocoagulation for macular edema in branch vein occlusion. *Am J Ophthalmol*. 1984 Sep;98(3):271–82.



- 43 Hayreh SS, Klugman MR, Podhajsky P, Servais GE, Perkins ES. Argon laser panretinal photocoagulation in ischemic central retinal vein occlusion. A 10-year prospective study. *Graefes Arch Klin Exp Ophthalmol*. 1990; 228(4):281–96.
- 44 Branch Vein Occlusion Study Group. Argon laser scatter photocoagulation for prevention of neovascularization and vitreous hemorrhage in branch vein occlusion. A randomized clinical trial. *Arch Ophthalmol*. 1986 Jan; 104(1):34–41.
- 45 Tan MH, McAllister IL, Gillies ME, Verma N, Banerjee G, Smithies LA, et al. Randomized controlled trial of intravitreal ranibizumab versus standard grid laser for macular edema following branch retinal vein occlusion. *Am J Ophthalmol*. 2014;157:237–247 e231.
- 46 Brown DM, Campochiaro PA, Bhisitkul RB, Ho AC, Gray S, Saroj N, et al. Sustained benefits from ranibizumab for macular edema following branch retinal vein occlusion: 12-month outcomes of a phase III study. *Ophthalmology*. 2011 Aug;118(8):1594–602.
- 47 Campochiaro PA, Heier JS, Feiner L, Gray S, Saroj N, Rundle AC, et al. Ranibizumab for macular edema following branch retinal vein occlusion: Six-month primary end point results of a phase iii study. *Ophthalmology*. 2010;117:1102–1112 e1101.
- 48 Clark WL, Boyer DS, Heier JS, Brown DM, Haller JA, Vitti R, et al. Intravitreal aflibercept for macular edema following branch retinal vein occlusion: 52-week results of the vibrant study. *Ophthalmology*. 2016 Feb;123(2):330–6.
- 49 Campochiaro PA, Hafiz G, Mir TA, Scott AW, Solomon S, Zimmer-Galler I, et al. Scatter photocoagulation does not reduce macular edema or treatment burden in patients with retinal vein occlusion: the relate trial. *Ophthalmology*. 2015 Jul;122(7):1426–37.
- 50 Aiello LP, Avery RL, Arrigg PG, Keyt BA, Jampel HD, Shah ST, et al. Vascular endothelial growth factor in ocular fluid of patients with diabetic retinopathy and other retinal disorders. *N Engl J Med*. 1994 Dec;331(22):1480–7.
- 51 Brown DM, Campochiaro PA, Singh RP, Li Z, Gray S, Saroj N, et al. Ranibizumab for macular edema following central retinal vein occlusion: Six-month primary end point results of a phase iii study. *Ophthalmology*. 2010;117:1124–1133 e1121.
- 52 Campochiaro PA, Hafiz G, Shah SM, Nguyen QD, Ying H, Do DV, et al. Ranibizumab for macular edema due to retinal vein occlusions: Implication of vegf as a critical stimulator. *Mol Ther*. 2008;16:791–799.
- 53 Noma H, Funatsu H, Yamasaki M, Tsukamoto H, Mimura T, Sone T, et al. Pathogenesis of macular edema with branch retinal vein occlusion and intraocular levels of vascular endothelial growth factor and interleukin-6. *Am J Ophthalmol*. 2005 Aug;140(2):256–61.
- 54 Pe'er J, Folberg R, Itin A, Gnessin H, Hemo I, Keshet E. Vascular endothelial growth factor upregulation in human central retinal vein occlusion. *Ophthalmology*. 1998 Mar;105(3):412–6.
- 55 Pielan A, Clark WL, Boyer DS, Ogura Y, Holz FG, Korobelnik JF, et al. Integrated results from the COPERNICUS and GALILEO studies. *Clin Ophthalmol*. 2017 Aug;11:1533–40.
- 56 Campochiaro PA, Sophie R, Pearlman J, Brown DM, Boyer DS, Heier JS, et al.; RETAIN Study Group. Long-term outcomes in patients with retinal vein occlusion treated with ranibizumab: the RETAIN study. *Ophthalmology*. 2014 Jan;121(1):209–19.
- 57 Heier JS, Campochiaro PA, Yau L, Li Z, Saroj N, Rubio RG, et al. Ranibizumab for macular edema due to retinal vein occlusions: long-term follow-up in the HORIZON trial. *Ophthalmology*. 2012 Apr;119(4):802–9.
- 58 Campochiaro PA, Brown DM, Awh CC, Lee SY, Gray S, Saroj N, et al. Sustained benefits from ranibizumab for macular edema following central retinal vein occlusion: twelve-month outcomes of a phase III study. *Ophthalmology*. 2011 Oct;118(10):2041–9.
- 59 Narayanan R, Panchal B, Das T, Chhablani J, Jalali S, Ali MH; MARVEL study group. A randomised, double-masked, controlled study of the efficacy and safety of intravitreal bevacizumab versus ranibizumab in the treatment of macular oedema due to branch retinal vein occlusion: MARVEL Report No. 1. *Br J Ophthalmol*. 2015 Jul;99(7):954–9.
- 60 Narayanan R, Panchal B, Stewart MW, Das T, Chhablani J, Jalali S, et al. Grid laser with modified pro re nata injection of bevacizumab and ranibizumab in macular edema due to branch retinal vein occlusion: MARVEL report no 2. *Clin Ophthalmol*. 2016 Jun;10:1023–9.
- 61 Campochiaro PA, Wyckoff CC, Singer M, Johnson R, Marcus D, Yau L, et al. Monthly versus as-needed ranibizumab injections in patients with retinal vein occlusion: the SHORE study. *Ophthalmology*. 2014 Dec;121(12):2432–42.
- 62 Agency EM. *Summary of product characteristics. Lucentis 10 mg/ml solution for injection*. Basel: Novartis; 2013.
- 63 Tadayoni R, Waldstein SM, Boscia F, Gerding H, Pearce I, Priglinger S, et al.; BRIGHTER study group. Individualized stabilization criteria-driven ranibizumab versus laser in branch retinal vein occlusion: Six-month results of brighter. *Ophthalmology*. 2016 Jun;123(6):1332–44.
- 64 Chatziralli I, Theodossiadis G, Kabanarou SA, Parikakis E, Xirou T, Mitropoulos P, et al. Ranibizumab versus dexamethasone implant for central retinal vein occlusion: the ranidex study. *Graefes archive for clinical and experimental ophthalmology*. = *Albrecht Von Graefes Arch Klin Exp Ophthalmol*. 2017; 255(10):1899–905.
- 65 Hattenbach LO, Feltgen N, Bertelmann T, Schmitz-Valckenberg S, Berk H, Eter N, et al.; COMRADE-B Study Group. Head-to-head comparison of ranibizumab PRN versus single-dose dexamethasone for branch retinal vein occlusion (COMRADE-B). *Acta Ophthalmol*. 2018 Feb;96(1):e10–8.
- 66 Hoerauf H, Feltgen N, Weiss C, Paulus EM, Schmitz-Valckenberg S, Pielan A, et al.; COMRADE-C Study Group. Clinical Efficacy and Safety of Ranibizumab Versus Dexamethasone for Central Retinal Vein Occlusion (COMRADE C): A European Label Study. *Am J Ophthalmol*. 2016 Sep;169:258–67.
- 67 Scott IU, VanVeldhuisen PC, Ip MS, Blodi BA, Oden NL, Awh CC, et al.; SCORE2 Investigator Group. Effect of bevacizumab vs aflibercept on visual acuity among patients with macular edema due to central retinal vein occlusion: the score2 randomized clinical trial. *JAMA*. 2017 May;317(20):2072–87.
- 68 Brown DM, Heier JS, Clark WL, Boyer DS, Vitti R, Berliner AJ, et al. Intravitreal aflibercept injection for macular edema secondary to central retinal vein occlusion: 1-year results from the phase 3 copernicus study. *Am J Ophthalmol*. 2013;155:429–437 e427.
- 69 Heier JS, Clark WL, Boyer DS, Brown DM, Vitti R, Berliner AJ, et al. Intravitreal aflibercept injection for macular edema due to central retinal vein occlusion: Two-year results from the copernicus study. *Ophthalmology*. 2014;121:1414–1420 e1411.
- 70 Ogura Y, Roeder J, Korobelnik JF, Holz FG, Simader C, Schmidt-Erfurth U, et al.; GALILEO Study Group. Intravitreal aflibercept for macular edema secondary to central retinal vein occlusion: 18-month results of the phase 3 GALILEO study. *Am J Ophthalmol*. 2014 Nov;158(5):1032–8.
- 71 Korobelnik JF, Holz FG, Roeder J, Ogura Y, Simader C, Schmidt-Erfurth U, et al.; GALILEO Study Group. Intravitreal aflibercept injection for macular edema resulting from central retinal vein occlusion: one-year results of the phase 3 galileo study. *Ophthalmology*. 2014 Jan;121(1):202–8.
- 72 Boyer D, Heier J, Brown DM, Clark WL, Vitti R, Berliner AJ, et al. Vascular endothelial growth factor Trap-Eye for macular edema secondary to central retinal vein occlusion: six-month results of the phase 3 COPERNICUS study. *Ophthalmology*. 2012 May;119(5):1024–32.
- 73 Holz FG, Roeder J, Ogura Y, Korobelnik JF, Simader C, Groetzbach G, et al. VEGF Trap-Eye for macular oedema secondary to central retinal vein occlusion: 6-month results of the phase III GALILEO study. *Br J Ophthalmol*. 2013 Mar;97(3):278–84.

- 74 Scott IU, VanVeldhuisen PC, Ip MS, Blodi BA, Oden NL, King J, et al.; SCORE2 Investigator Group. Baseline factors associated with 6-month visual acuity and retinal thickness outcomes in patients with macular edema secondary to central retinal vein occlusion or hemiretinal vein occlusion: Score2 study report 4. *JAMA Ophthalmol*. 2017 Jun;135(6):639–49.
- 75 Koss MJ, Pfister M, Rothweiler F, Michaelis M, Cinatl J, Schubert R, et al. Comparison of cytokine levels from undiluted vitreous of untreated patients with retinal vein occlusion. *Acta Ophthalmol*. 2012 Mar;90(2):e98–103.
- 76 Noma H, Funatsu H, Mimura T, Harino S, Hori S. Vitreous levels of interleukin-6 and vascular endothelial growth factor in macular edema with central retinal vein occlusion. *Ophthalmology*. 2009 Jan;116(1):87–93.
- 77 Noma H, Minamoto A, Funatsu H, Tsukamoto H, Nakano K, Yamashita H, et al. Intravitreal levels of vascular endothelial growth factor and interleukin-6 are correlated with macular edema in branch retinal vein occlusion. *Graefes Arch Clin Exp Ophthalmol*. 2006 Mar;244(3):309–15.
- 78 Jeanneteau F, Garabedian MJ, Chao MV. Activation of Trk neurotrophin receptors by glucocorticoids provides a neuroprotective effect. *Proc Natl Acad Sci USA*. 2008 Mar;105(12):4862–7.
- 79 Flynn HW Jr, Scott IU. Intravitreal triamcinolone acetate for macular edema associated with diabetic retinopathy and venous occlusive disease: it's time for clinical trials. *Arch Ophthalmol*. 2005 Feb;123(2):258–9.
- 80 Blumenkranz MS. New therapy for central retinal vein occlusion: are intravitreal steroids a possible answer? *Arch Ophthalmol*. 2005 Feb;123(2):259–61.
- 81 Campochiaro PA, Hafiz G, Mir TA, Scott AW, Sophie R, Shah SM, et al. Pro-permeability factors after dexamethasone implant in retinal vein occlusion; the ozurdex for retinal vein occlusion (orvo) study. *Am J Ophthalmol*. 2015;160:313–321 e319.
- 82 Daruich A, Matet A, Moulin A, Kowalczyk L, Nicolas M, Sellam A, et al. Mechanisms of macular edema: beyond the surface. *Prog Retin Eye Res*. 2018 Mar;63:20–68.
- 83 Rezar-Dreindl S, Eibenberger K, Pollreis A, Bühl W, Georgopoulos M, Krall C, et al. Effect of intravitreal dexamethasone implant on intra-ocular cytokines and chemokines in eyes with retinal vein occlusion. *Acta Ophthalmol*. 2017 Mar;95(2):e119–27.
- 84 Eibenberger K, Schmetterer L, Rezar-Dreindl S, Wozniak P, Told R, Mylonas G, et al. Effects of intravitreal dexamethasone implants on retinal oxygen saturation, vessel diameter, and retrobulbar blood flow velocity in the secondary to rvo. *Invest Ophthalmol Vis Sci*. 2017 Oct;58(12):5022–9.
- 85 Scott IU, Ip MS, VanVeldhuisen PC, Oden NL, Blodi BA, Fisher M, et al.; SCORE Study Research Group. A randomized trial comparing the efficacy and safety of intravitreal triamcinolone with standard care to treat vision loss associated with macular edema secondary to branch retinal vein occlusion: the Standard Care vs Corticosteroid for Retinal Vein Occlusion (SCORE) study report 6. *Arch Ophthalmol*. 2009 Sep;127(9):1115–28.
- 86 Haller JA, Bandello F, Belfort R Jr, Blumenkranz MS, Gillies M, Heier J, et al.; OZURDEX GENEVA Study Group. Randomized, sham-controlled trial of dexamethasone intravitreal implant in patients with macular edema due to retinal vein occlusion. *Ophthalmology*. 2010;117(6):1134–1146 e1133.
- 87 Haller JA, Bandello F, Belfort R Jr, Blumenkranz MS, Gillies M, Heier J, et al.; Ozurdex GENEVA Study Group. Dexamethasone intravitreal implant in patients with macular edema related to branch or central retinal vein occlusion twelve-month study results. *Ophthalmology*. 2011 Dec;118(12):2453–60.
- 88 Chang-Lin JE, Attar M, Acheampong AA, Robinson MR, Whitcup SM, Kuppermann BD, et al. Pharmacokinetics and pharmacodynamics of a sustained-release dexamethasone intravitreal implant. *Invest Ophthalmol Vis Sci*. 2011 Jan;52(1):80–6.
- 89 Li D, Taniguchi EV, Cai S, Paschalis EI, Wang H, Miller JB, et al. Comparison of swept-source and enhanced depth imaging spectral-domain optical coherence tomography in quantitative characterisation of the optic nerve head. *Br J Ophthalmol*. 2017 Mar;101(3):299–304.
- 90 Moisseiev E, Goldstein M, Waisbourd M, Barak A, Loewenstein A. Long-term evaluation of patients treated with dexamethasone intravitreal implant for macular edema due to retinal vein occlusion. *Eye (Lond)*. 2013 Jan;27(1):65–71.
- 91 Alshahrani ST, Dolz-Marco R, Gallego-Pinazo R, Diaz-Llopis M, Arevalo JF; KKESH International Collaborative Retina Study Group. Intravitreal dexamethasone implant for the treatment of refractory macular edema in retinal vascular diseases: results of the kkeshe international collaborative retina study group. *Retina*. 2016 Jan;36(1):131–6.
- 92 Garweg JG, Zandi S. Retinal vein occlusion and the use of a dexamethasone intravitreal implant (Ozurdex®) in its treatment. *Graefes Arch Klin Exp Ophthalmol*. 2016;254:1257–65.
- 93 Lam WC, Albani DA, Yoganathan P, Chen JC, Kherani A, Maberley DA, et al. Real-world assessment of intravitreal dexamethasone implant (0.7 mg) in patients with macular edema: the CHROME study. *Clin Ophthalmol*. 2015 Jul;9:1255–68.
- 94 Maggio E, Polito A, Guerriero M, Pertile G. Intravitreal dexamethasone implant for macular edema secondary to retinal vein occlusion: 12-month follow-up and prognostic factors. *Ophthalmologica*. 2014;232(4):207–15.
- 95 Mayer WJ, Wolf A, Kernt M, Kook D, Kampik A, Ulbig M, et al. Twelve-month experience with Ozurdex for the treatment of macular edema associated with retinal vein occlusion. *Eye (Lond)*. 2013 Jul;27(7):816–22.
- 96 Pommier S, Meyer F, Guigou S, Barthelemy T, Gobert F, Hajjar C, et al. Long-Term Real-Life Efficacy and Safety of Repeated Ozurdex® Injections and Factors Associated with Macular Edema Resolution after Retinal Vein Occlusion: The REMIDO 2 Study. *Ophthalmologica*. 2016;236(4):186–92.
- 97 Querques G, Cascavilla ML, Cavallero E, Triolo G, Querques L, Lattanzio R, et al. Changes in macular function after ozurdex for retinal vein occlusion. *Optom Vis Sci*. 2014 Jul;91(7):760–8.
- 98 Veritti D, Macor S, Lanzetta P. Early effects of dexamethasone implant on macular morphology and visual function in patients with macular edema secondary to retinal vein occlusion. *Ophthalmologica*. 2014;232(3):144–8.
- 99 Winterhalter S, Vom Brocke GA, Klamann MK, Müller B, Joussem AM. Monthly microperimetry (MP1) measurement of macular sensitivity after dexamethasone implantation (Ozurdex) in retinal vein occlusions. *Graefes Arch Clin Exp Ophthalmol*. 2015 Nov;253(11):1873–82.
- 100 Coscas G, Augustin A, Bandello F, de Smet MD, Lanzetta P, Staurenghi G, et al. Retreatment with Ozurdex for macular edema secondary to retinal vein occlusion. *Eur J Ophthalmol*. 2014 Jan-Feb;24(1):1–9.
- 101 Coscas G, Loewenstein A, Augustin A, Bandello F, Battaglia Parodi M, Lanzetta P, et al. Management of retinal vein occlusion—consensus document. *Ophthalmologica*. 2011;226(1):4–28.
- 102 Korobelnik JF, Kodjikian L, Delcourt C, Gualino V, Leaback R, Pinchinat S, et al. Two-year, prospective, multicenter study of the use of dexamethasone intravitreal implant for treatment of macular edema secondary to retinal vein occlusion in the clinical setting in France. *Graefes Arch Clin Exp Ophthalmol*. 2016 Dec;254(12):2307–18.
- 103 Bakri SJ, Omar AF, Iezzi R, Kapoor KG. Evaluation of multiple dexamethasone intravitreal implants in patients with macular edema associated with retinal vein occlusion. *Retina*. 2016 Mar;36(3):552–7.
- 104 Eter N, Mohr A, Wachtlin J, Feltgen N, Shirlaw A, Leaback R; German Ozurdex in RVO Real World Study Group. Dexamethasone intravitreal implant in retinal vein occlusion: Real-life data from a prospective, multicenter clinical trial. *Graefes Arch Klin Exp Ophthalmol*. 2017;255(1):77–87.
- 105 Yeh WS, Haller JA, Lanzetta P, Kuppermann BD, Wong TY, Mitchell P, et al. Effect of the duration of macular edema on clinical outcomes in retinal vein occlusion treated with dexamethasone intravitreal implant. *Ophthalmology*. 2012 Jun;119(6):1190–8.

- 106 Lin CJ, Chen HS, Su CW, Tien PT, Lin JM, Chen WL, et al. The effect of age and initial central retinal thickness on earlier need of repeat ozurdex treatment for macular edema due to retinal vein occlusion: A retrospective case series. *J Ocul Pharmacol Ther.* 2017 Dec;33(10):763–72.
- 107 Malclès A, Dot C, Voirin N, Vié AL, Agard É, Bellocq D, et al. Safety of intravitreal dexamethasone implant (ozurdex): the safodex study. Incidence and risk factors of ocular hypertension. *Retina.* 2017 Jul;37(7):1352–9.
- 108 Guignier B, Subilia-Guignier A, Fournier I, Ballonzoli L, Speeg-Schatz C, Gaucher D. Prospective pilot study: efficacy of intravitreal dexamethasone and bevacizumab injections in the treatment of macular oedema associated with branch retinal vein occlusion. *Ophthalmologica.* 2013;230(1):43–9.
- 109 Mayer WJ, Hadjigoli A, Wolf A, Herold T, Haritoglou C. [Comparison of Intravitreal Dexamethasone Implant versus Intravitreal Ranibizumab as a First-Line Treatment of Macular Oedema due to Retinal Vein Occlusion]. *Klin Monbl Augenheilkd.* 2015 Nov;232(11):1289–96.
- 110 Gu X, Yu X, Song S, Dai H. Intravitreal dexamethasone implant versus intravitreal ranibizumab for the treatment of macular edema secondary to retinal vein occlusion in a chinese population. *Ophthalmic Res.* 2017; 58(1):8–14.
- 111 Ozkok A, Saleh OA, Sigford DK, Heroman JW, Schaal S. The omar study: comparison of ozurdex and triamcinolone acetonide for refractory cystoid macular edema in retinal vein occlusion. *Retina.* 2015 Jul;35(7):1393–400.
- 112 Gado AS, Macky TA. Dexamethasone intravitreal implant versus bevacizumab for central retinal vein occlusion-related macular oedema: a prospective randomized comparison. *Clin Exp Ophthalmol.* 2014 Sep-Oct;42(7):650–5.
- 113 Singer MA, Jansen ME, Tyler L, Woods P, Ansari F, Jain U, et al. Long-term results of combination therapy using anti-VEGF agents and dexamethasone intravitreal implant for retinal vein occlusion: an investigation for case series. *Clin Ophthalmol.* 2016 Dec;11:31–8.
- 114 Pichi F, Specchia C, Vitale L, Lembo A, Morara M, Veronese C, et al. Combination therapy with dexamethasone intravitreal implant and macular grid laser in patients with branch retinal vein occlusion. *Am J Ophthalmol.* 2014;157:607–615 e601.
- 115 Mayer WJ, Remy M, Wolf A, Kook D, Kampik A, Ulbig M, et al. Comparison of intravitreal bevacizumab upload followed by a dexamethasone implant versus dexamethasone implant monotherapy for retinal vein occlusion with macular edema. *Ophthalmologica.* 2012;228(2):110–6.
- 116 Zheng A, Chin EK, Almeida DR, Tsang SH, Mahajan VB. Combined vitrectomy and intravitreal dexamethasone (ozurdex) sustained-release implant. *Retina.* 2016 Nov; 36(11):2087–92.
- 117 Balal S, Than J, Tekriwal S, Lobo A. Dexamethasone intravitreal implant therapy for retinal vein occlusion macular oedema and conversion to ranibizumab in clinical practice. *Ophthalmologica.* 2018;239(1):36–44.
- 118 Stefansson E. Physiology of vitreous surgery. *Graefes Arch Klin Exp Ophthalmol.* 2009; 247:147–63.
- 119 Lam HD, Blumenkranz MS. Treatment of central retinal vein occlusion by vitrectomy with lysis of vitreopapillary and epipapillary adhesions, subretinal peripapillary tissue plasminogen activator injection, and photocoagulation. *Am J Ophthalmol.* 2002 Oct; 134(4):609–11.
- 120 Yeshaya A, Treister G. Pars plana vitrectomy for vitreous hemorrhage and retinal vein occlusion. *Ann Ophthalmol.* 1983 Jul;15(7): 615–7.
- 121 Furino C, Ferrari TM, Boscica F, Cardascia N, Sborgia L, Reibaldi M, et al. Combined radial optic neurotomy, internal limiting membrane peeling, and intravitreal triamcinolone acetonide for central retinal vein occlusion. *Ophthalmic Surg Lasers Imaging.* 2005;36:422–425.
- 122 DeCroos FC, Shuler RK Jr, Stinnett S, Fekrat S. Pars plana vitrectomy, internal limiting membrane peeling, and panretinal endophotocoagulation for macular edema secondary to central retinal vein occlusion. *Am J Ophthalmol.* 2009;147:627–633 e621.
- 123 Hahn P. Successful treatment of neovascular age-related macular degeneration following single bevacizumab failure using aflibercept in a vitrectomized eye. *Clin Ophthalmol.* 2014 Oct;8:2129–31.
- 124 Opremcak EM, Bruce RA, Lomeo MD, Ridenour CD, Letson AD, Rehmar AJ. Radial optic neurotomy for central retinal vein occlusion: a retrospective pilot study of 11 consecutive cases. *Retina.* 2001;21(5):408–15.
- 125 Vasco-Posada J. Modification of the circulation in the posterior pole of the eye. *Ann Ophthalmol.* 1972 Jan;4(1):48–59.
- 126 Dev S, Buckley EG. Optic nerve sheath decompression for progressive central retinal vein occlusion. *Ophthalmic Surg Lasers.* 1999 Mar;30(3):181–4.
- 127 García-Arumi J, Boixadera A, Martínez-Castillo V, Castillo R, Dou A, Corcostegui B. Chorioretinal anastomosis after radial optic neurotomy for central retinal vein occlusion. *Arch Ophthalmol.* 2003 Oct;121(10): 1385–91.
- 128 García-Arumi J, Boixadera A, Martínez-Castillo V, Montolio M, Verdugo A, Corcostegui B. Radial optic neurotomy in central retinal vein occlusion: comparison of outcome in younger vs older patients. *Am J Ophthalmol.* 2007 Jan;143(1):134–40.
- 129 García-Arumi J, Boixadera A, Martínez-Castillo V, Blasco H, Lavaque A, Corcostegui B. Radial optic neurotomy for management of hemispherical retinal vein occlusion. *Arch Ophthalmol.* 2006 May;124(5):690–5.
- 130 Opremcak EM, Rehmar AJ, Ridenour CD, Kurz DE. Radial optic neurotomy for central retinal vein occlusion: 117 consecutive cases. *Retina.* 2006 Mar;26(3):297–305.
- 131 Arevalo JF, García RA, Wu L, Rodríguez FJ, Dalma-Weiszhausz J, Quiroz-Mercado H, et al.; Pan-American Collaborative Retina Study Group. Radial optic neurotomy for central retinal vein occlusion: results of the Pan-American Collaborative Retina Study Group (PACORES). *Retina.* 2008 Oct;28(8): 1044–52.
- 132 Aggermann T, Brunner S, Krebs I, Haas P, Womastek I, Brannath W, et al.; ROVO Study Group. A prospective, randomised, multicenter trial for surgical treatment of central retinal vein occlusion: results of the Radial Optic Neurotomy for Central Vein Occlusion (ROVO) study group. *Graefes Arch Clin Exp Ophthalmol.* 2013 Apr; 251(4):1065–72.
- 133 Martínez-Jardón CS, Meza-de Regil A, Dalma-Weiszhausz J, Leizaola-Fernández C, Morales-Cantón V, Guerrero-Naranjo JL, et al. Radial optic neurotomy for ischaemic central vein occlusion. *Br J Ophthalmol.* 2005 May;89(5):558–61.
- 134 Crama N, Gualino V, Restori M, Charteris DG. Central retinal vessel blood flow after surgical treatment for central retinal vein occlusion. *Retina.* 2010 Nov-Dec;30(10):1692–7.
- 135 Skevas C, Wagenfeld L, Feucht M, Galambos P, Richard G, Zeitz O. Radial optic neurotomy in central retinal vein occlusion does not influence ocular hemodynamics. *Ophthalmologica.* 2011;225(1):41–6.
- 136 Weizer JS, Stinnett SS, Fekrat S. Radial optic neurotomy as treatment for central retinal vein occlusion. *Am J Ophthalmol.* 2003 Nov; 136(5):814–9.
- 137 Takahashi MK, Hikichi T, Akiba J, Yoshida A, Trempe CL. Role of the vitreous and macular edema in branch retinal vein occlusion. *Ophthalmic Surg Lasers.* 1997 Apr;28(4): 294–9.
- 138 Scott IU. Vitreoretinal surgery for complications of branch retinal vein occlusion. *Curr Opin Ophthalmol.* 2002 Jun;13(3):161–6.
- 139 Noma H, Funatsu H, Sakata K, Mimura T, Hori S. Macular microcirculation before and after vitrectomy for macular edema with branch retinal vein occlusion. *Graefes Arch Klin Exp Ophthalmol.* 2010;248(3): 443–5.
- 140 Raszewska-Steglinska M, Gozdek P, Cisiecki S, Michalewska Z, Michalewski J, Nawrocki J. Pars plana vitrectomy with ILM peeling for macular edema secondary to retinal vein occlusion. *Eur J Ophthalmol.* 2009 Nov-Dec;19(6):1055–62.



- 141 Arai M, Yamamoto S, Mitamura Y, Sato E, Sugawara T, Mizunoya S. Efficacy of vitrectomy and internal limiting membrane removal for macular edema associated with branch retinal vein occlusion. *Ophthalmologica*. 2009;223(3):172–6.
- 142 Osterloh MD, Charles S. Surgical decompression of branch retinal vein occlusions. *Arch Ophthalmol*. 1988 Oct;106(10):1469–71.
- 143 Frangieh GT, Green WR, Barraquer-Somers E, Finkelstein D. Histopathologic study of nine branch retinal vein occlusions. *Arch Ophthalmol*. 1982 Jul;100(7):1132–40.
- 144 Kumar B, Yu DY, Morgan WH, Barry CJ, Constable IJ, McAllister IL. The distribution of angioarchitectural changes within the vicinity of the arteriovenous crossing in branch retinal vein occlusion. *Ophthalmology*. 1998 Mar;105(3):424–7.
- 145 Opremcak EM, Bruce RA. Surgical decompression of branch retinal vein occlusion via arteriovenous crossing sheathotomy: a prospective review of 15 cases. *Retina*. 1999; 19(1):1–5.
- 146 Mester U, Dillinger P. Vitrectomy with arteriovenous decompression and internal limiting membrane dissection in branch retinal vein occlusion. *Retina*. 2002 Dec; 22(6):740–6.
- 147 García-Arumí J, Martínez-Castillo V, Boixadera A, Blasco H, Corcostegui B. Management of macular edema in branch retinal vein occlusion with sheathotomy and recombinant tissue plasminogen activator. *Retina*. 2004 Aug;24(4):530–40.
- 148 Chung EJ, Lee H, Koh HJ. Arteriovenous crossing sheathotomy versus intravitreal triamcinolone acetonide injection for treatment of macular edema associated with branch retinal vein occlusion. *Graefes Arch Clin Exp Ophthalmol*. 2008 Jul;246(7):967–74.
- 149 Kumagai K, Furukawa M, Ogino N, Uemura A, Larson E. Long-term outcomes of vitrectomy with or without arteriovenous sheathotomy in branch retinal vein occlusion. *Retina*. 2007 Jan;27(1):49–54.
- 150 The Eye Disease Case-Control Study Group. Risk factors for central retinal vein occlusion. *Arch Ophthalmol*. 1996 May;114(5): 545–54.
- 151 Bertelsen M, Linneberg A, Christoffersen N, Vorum H, Gade E, Larsen M. Mortality in patients with central retinal vein occlusion. *Ophthalmology*. 2014 Mar;121(3):637–42.
- 152 Tsaloumas MD, Kirwan J, Vinall H, O’Leary MB, Prior P, Kritzinger EE, et al. Nine year follow-up study of morbidity and mortality in retinal vein occlusion. *Eye (Lond)*. 2000 Dec;14(Pt 6):821–7.
- 153 Ho JD, Liou SW, Lin HC. Retinal vein occlusion and the risk of stroke development: A five-year follow-up study. *Am J Ophthalmol* 2009;147:283–290 e282.
- 154 Cugati S, Wang JJ, Knudtson MD, Rochtchina E, Klein R, Klein BE, et al. Retinal vein occlusion and vascular mortality: pooled data analysis of 2 population-based cohorts. *Ophthalmology*. 2007 Mar;114(3):520–4.
- 155 Wong TY, Larsen EK, Klein R, Mitchell P, Couper DJ, Klein BE, et al. Cardiovascular risk factors for retinal vein occlusion and arteriolar emboli: the Atherosclerosis Risk in Communities & Cardiovascular Health studies. *Ophthalmology*. 2005 Apr;112(4): 540–7.
- 156 Hu CC, Ho JD, Lin HC. Retinal vein occlusion and the risk of acute myocardial infarction (correction of infraction): a 3-year follow-up study. *Br J Ophthalmol*. 2009 Jun; 93(6):717–20.
- 157 Mansour AM, Walsh JB, Henkind P. Mortality and morbidity in patients with central retinal vein occlusion. *Ophthalmologica*. 1992;204(4):199–203.
- 158 Schlegl T, Waldstein SM, Bogunovic H, Endstraßer F, Sadeghipour A, Philip AM, et al. Fully automated detection and quantification of macular fluid in OCT using deep learning. *Ophthalmology*. 2018 Apr;125(4): 549–558.